

A New Look to the Anterior Segment

“The Power of Combined AS-OCT and Placido imaging”

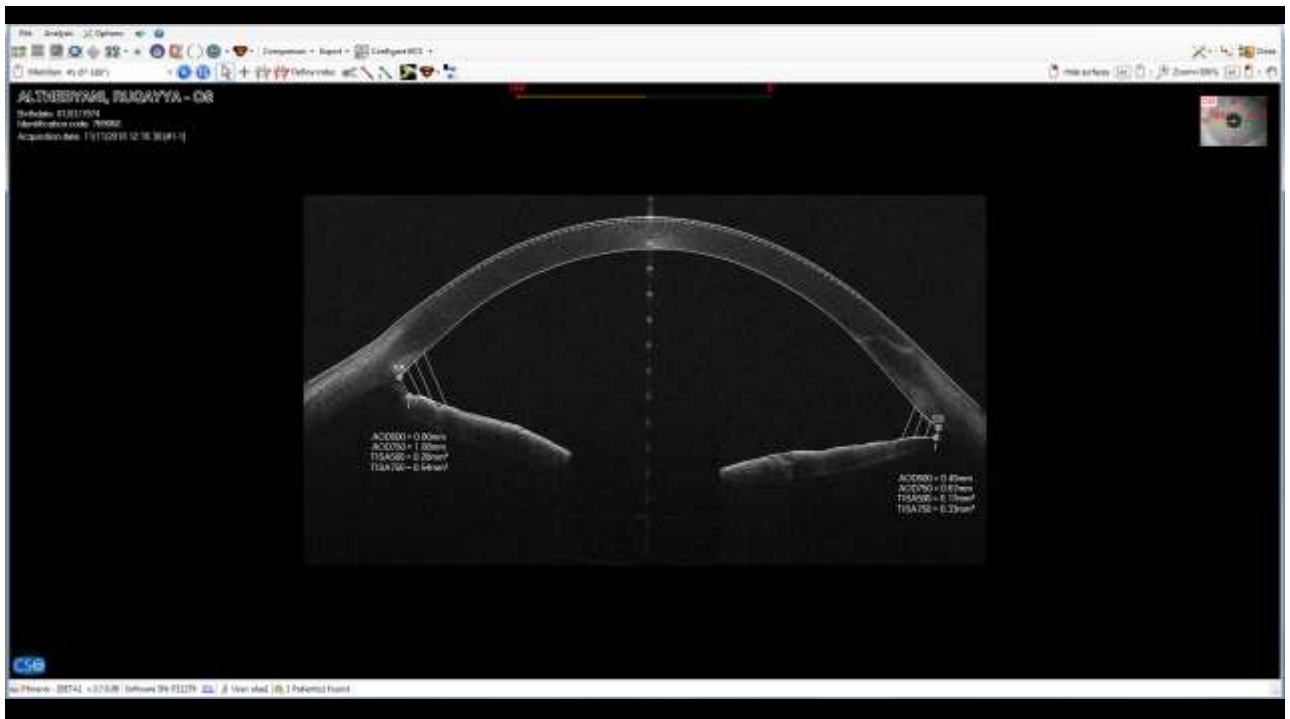
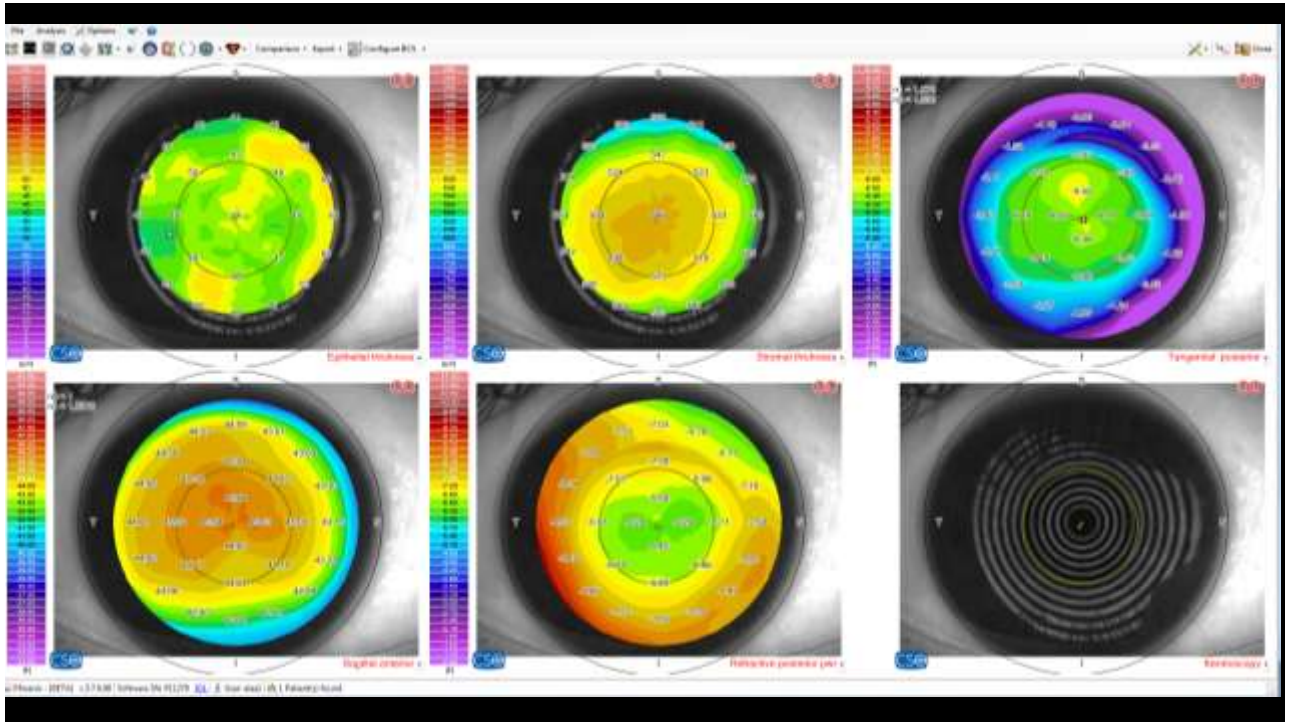
Alaa Eldanasoury, MD, FRCS

Magrabi Hospitals & Centers

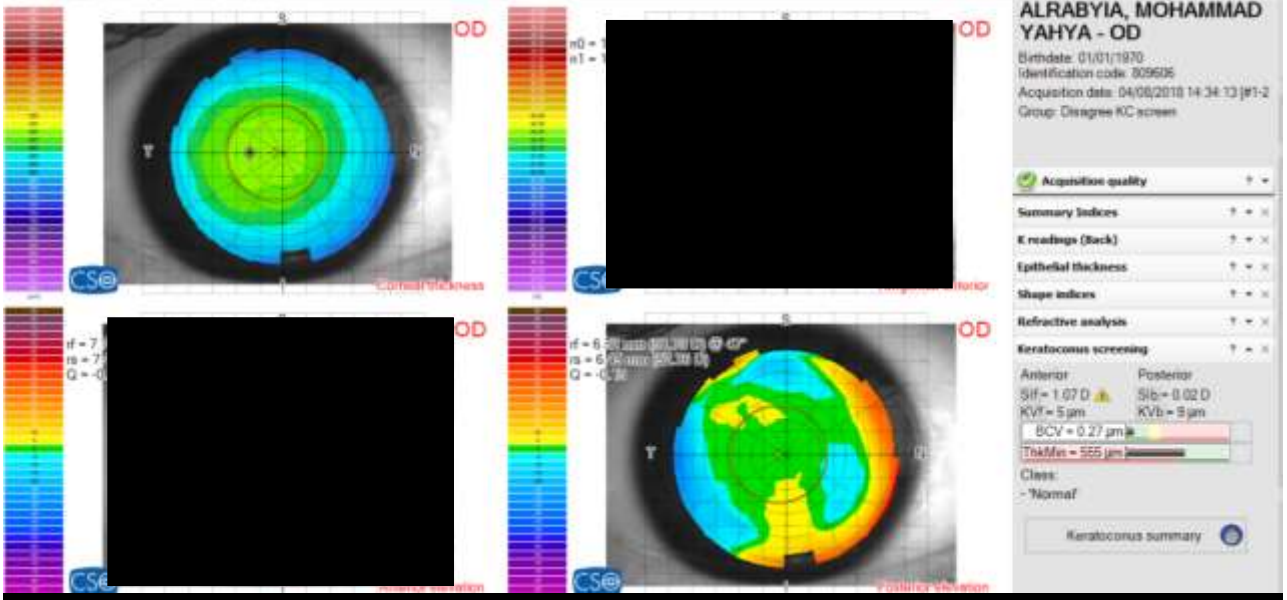
Financial Disclosures

Consultant to:

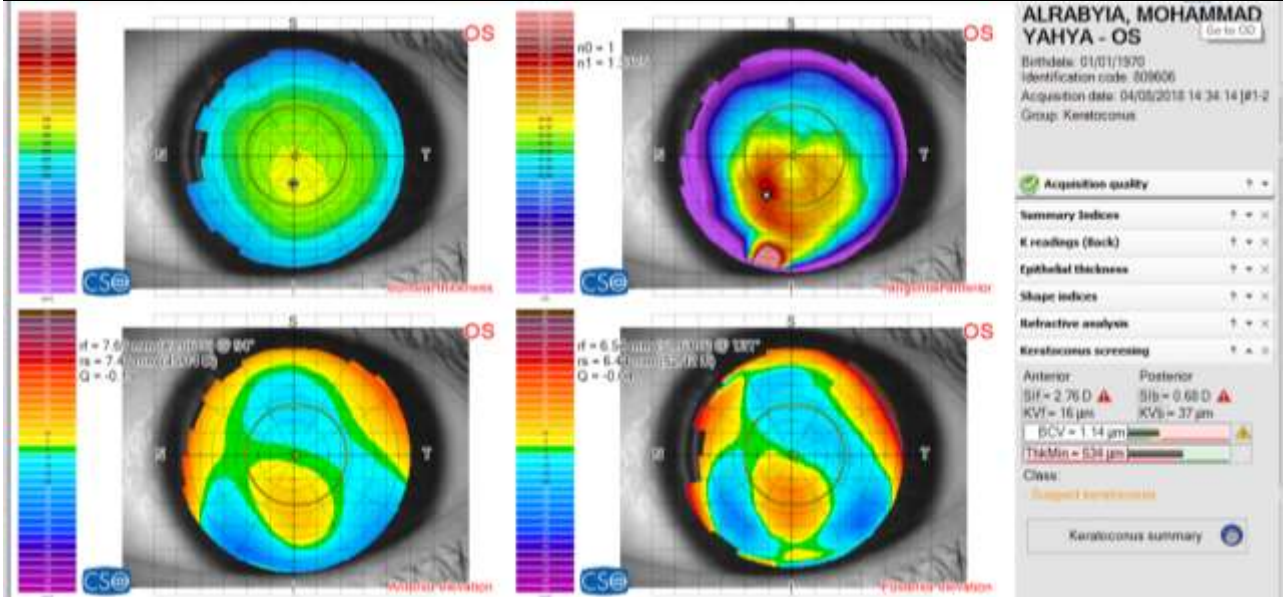
- STAAR Surgical.
- NIDEK Co.
- PhysIOL.



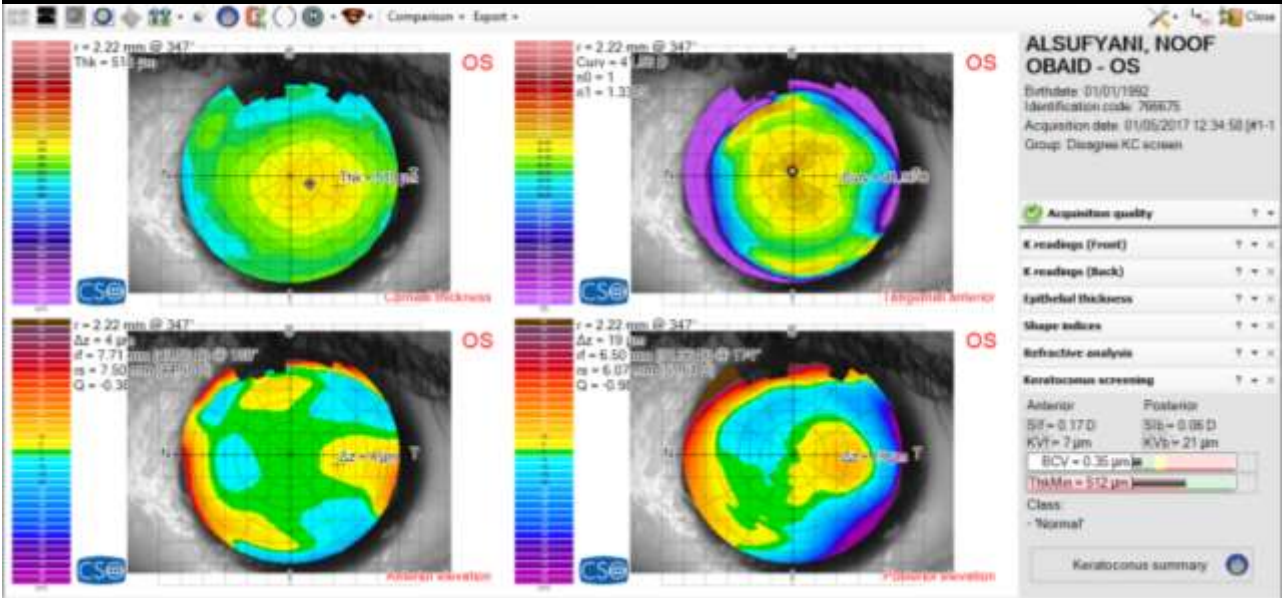
Placido



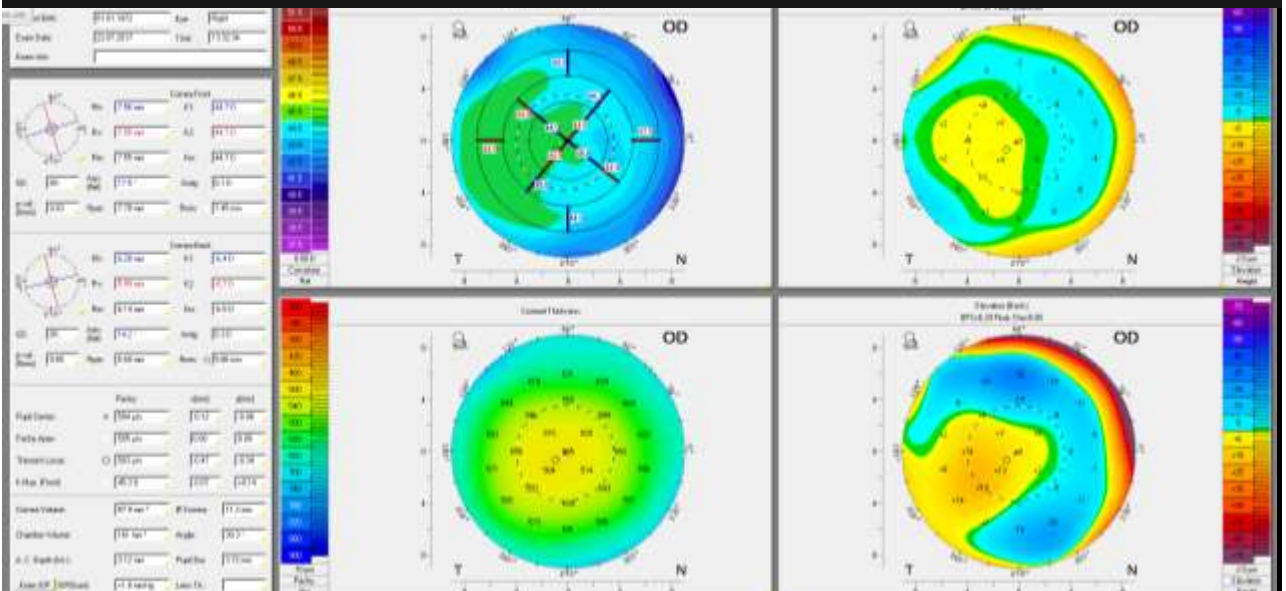
Other Eye!



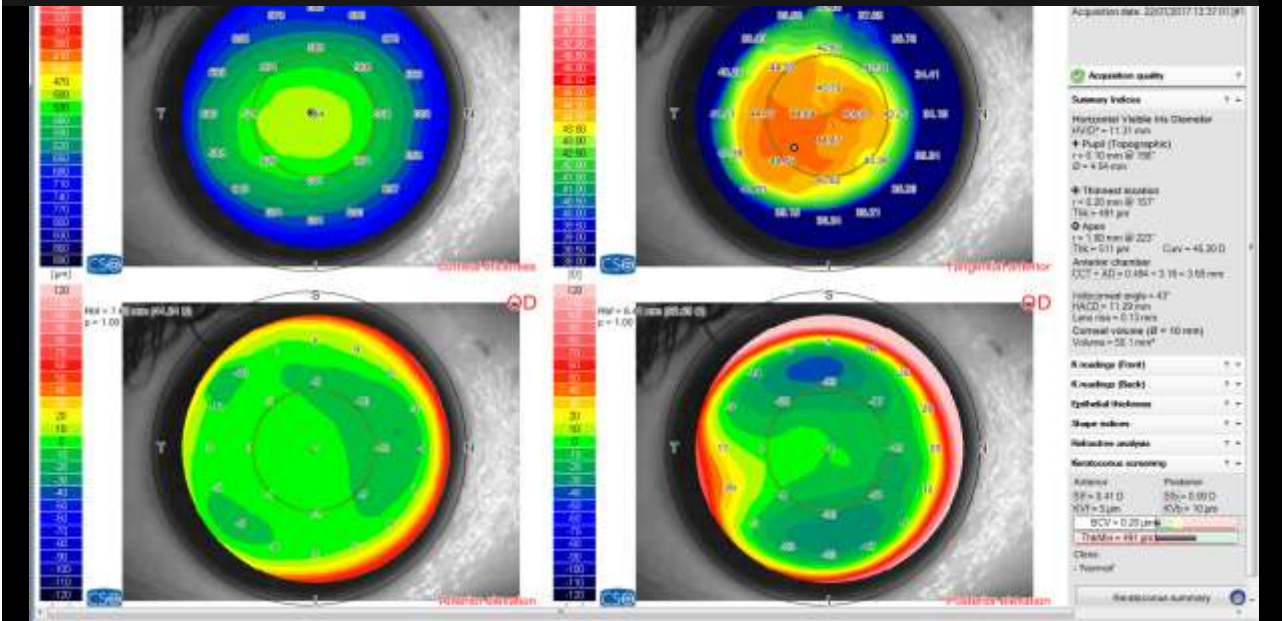
Importance of Posterior Elevation Map



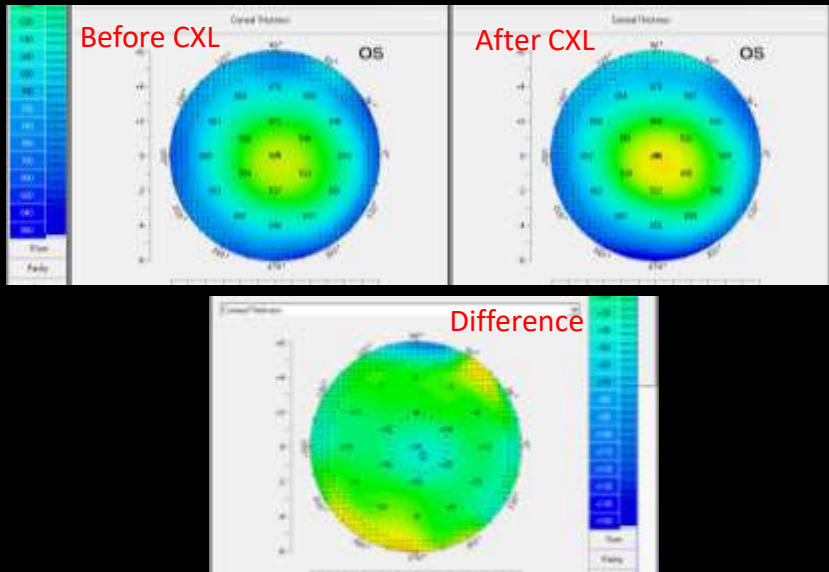
OCT vs Scheimpflug

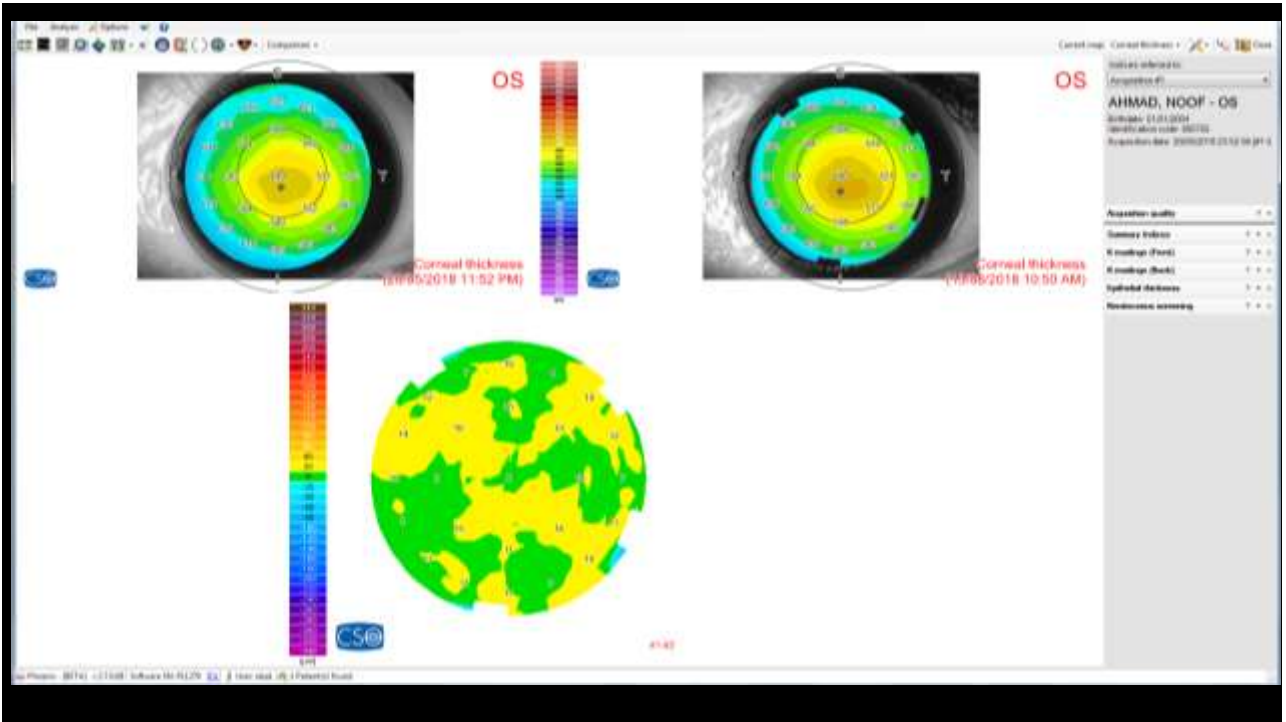


OCT vs Scheimpflug



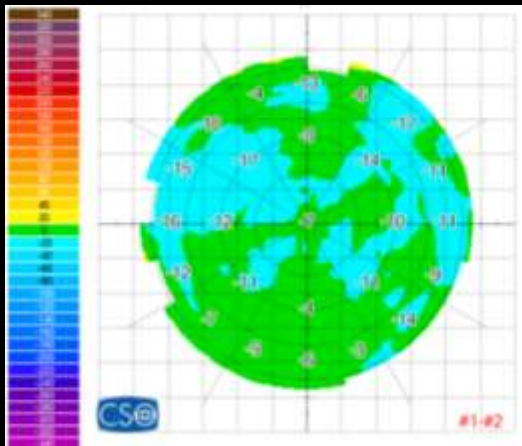
Corneal Thickness 6 months after CXL



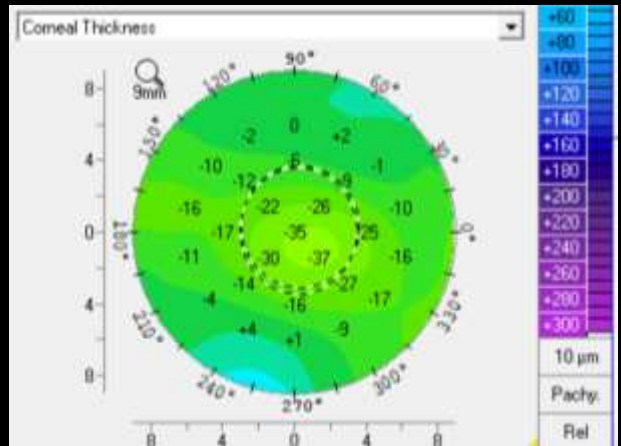


Differential Thickness Maps after CXL:

Anterior Segment OCT
Postop - preop

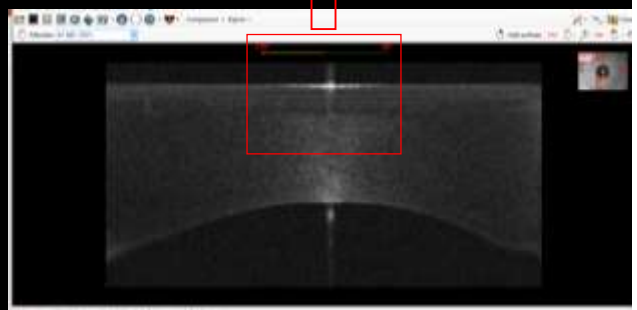
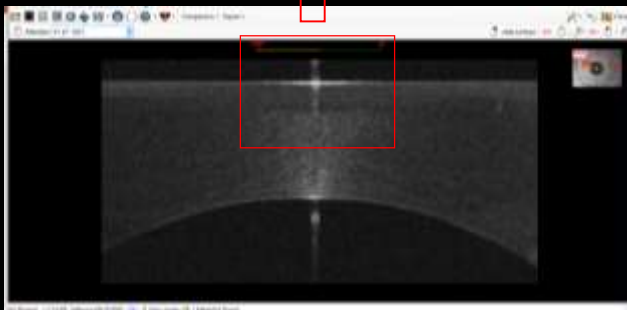
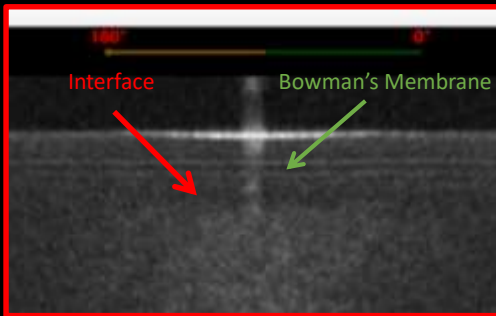
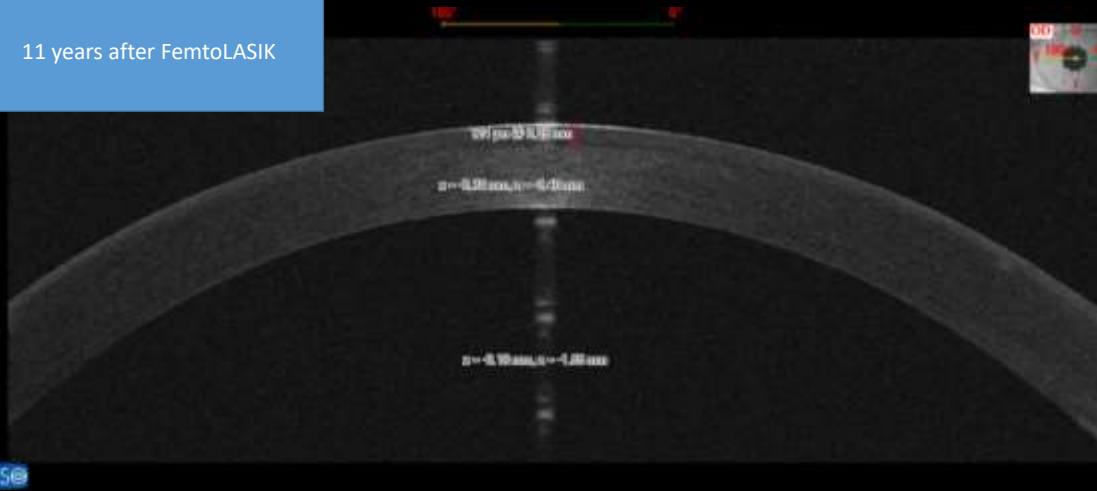


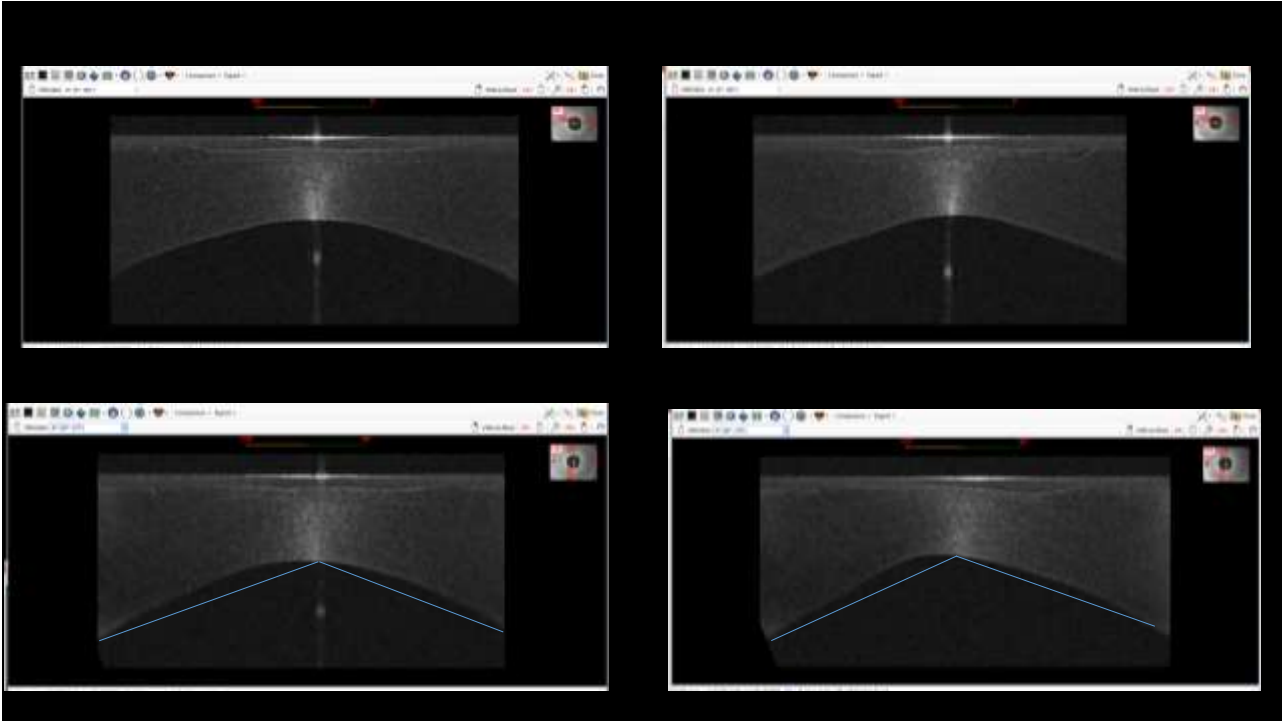
Scheimpflug Tomography
Postop - preop



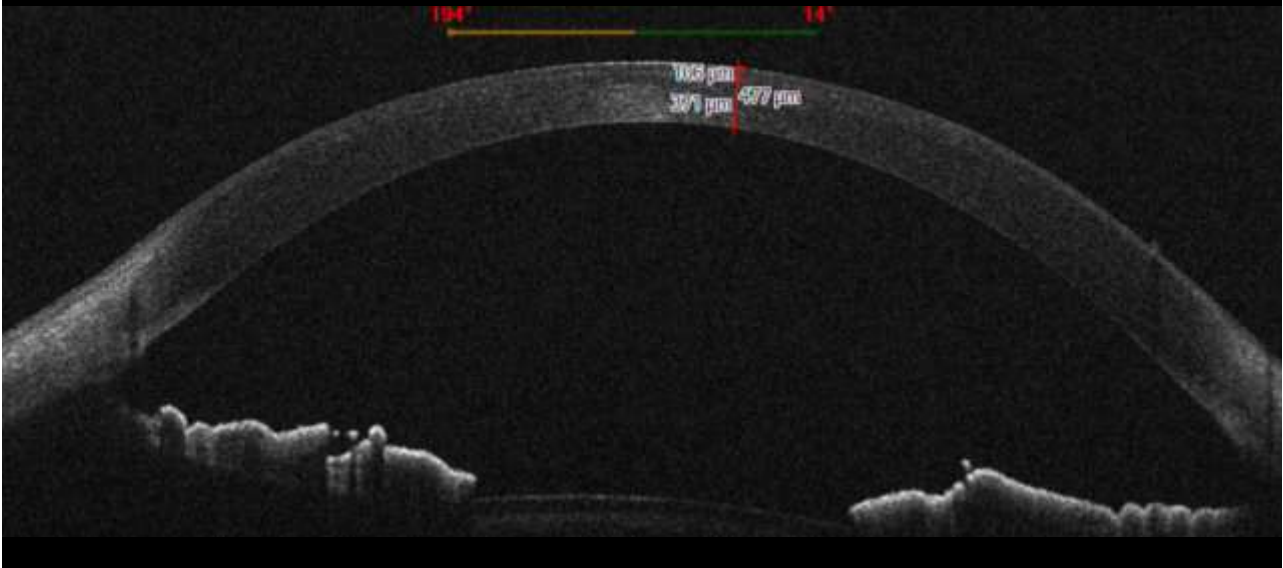
LASIK Flap

11 years after FemtoLASIK

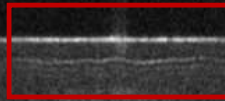
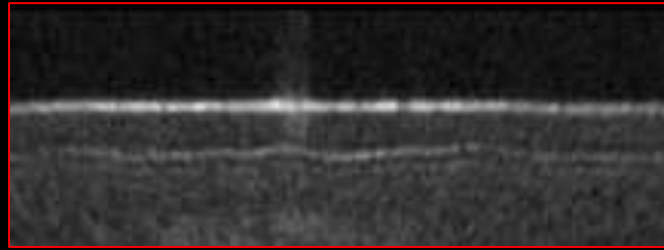




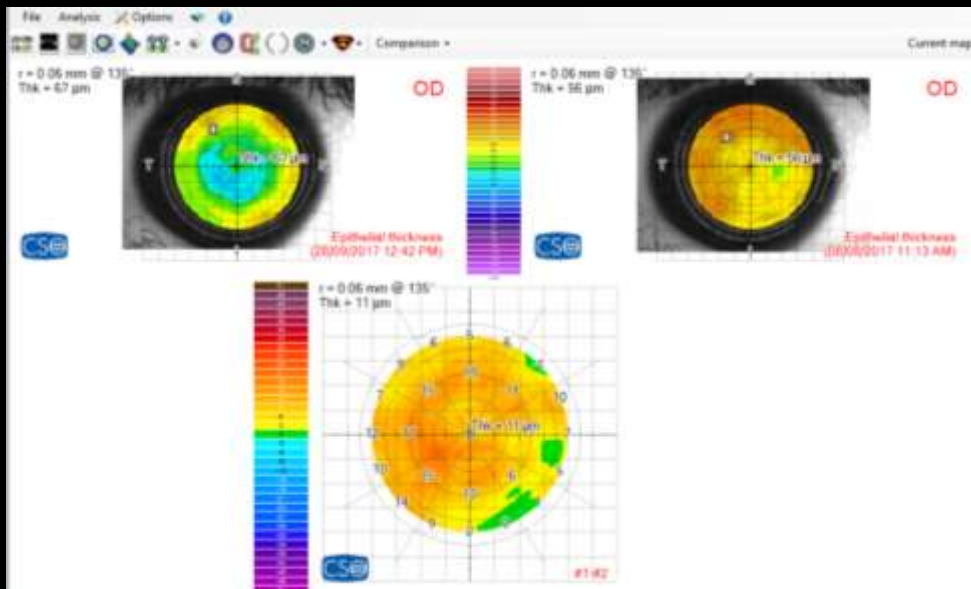
SMILE Cap



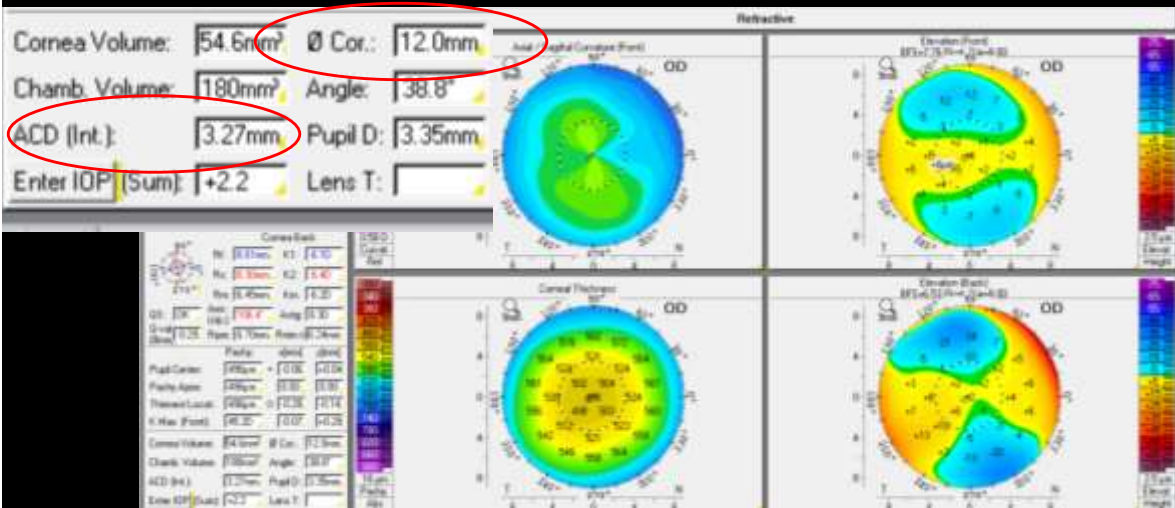
1 Year after SMILE



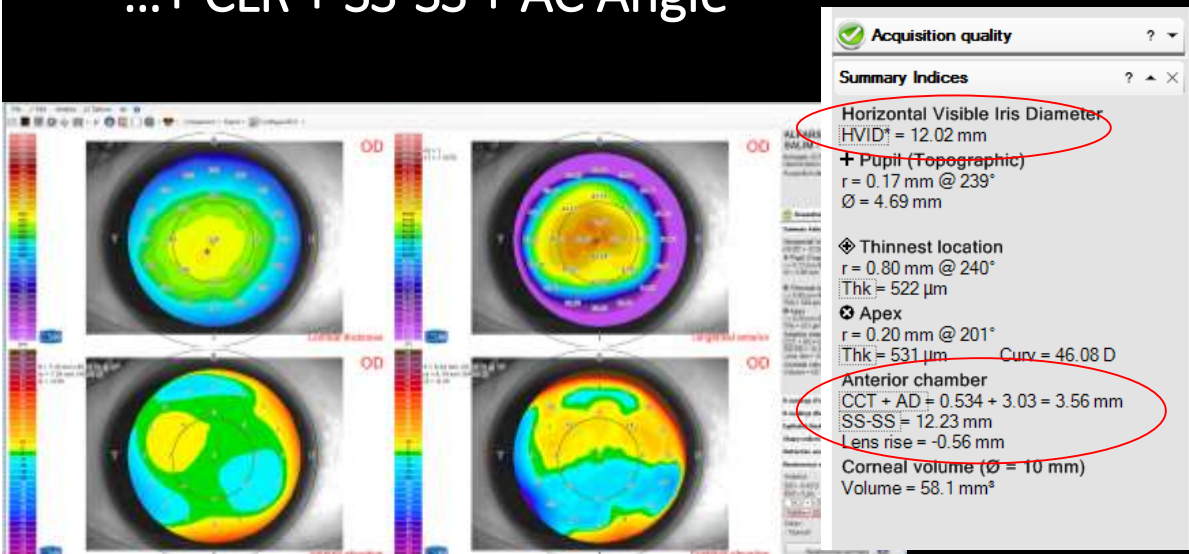
Epithelial Remodeling

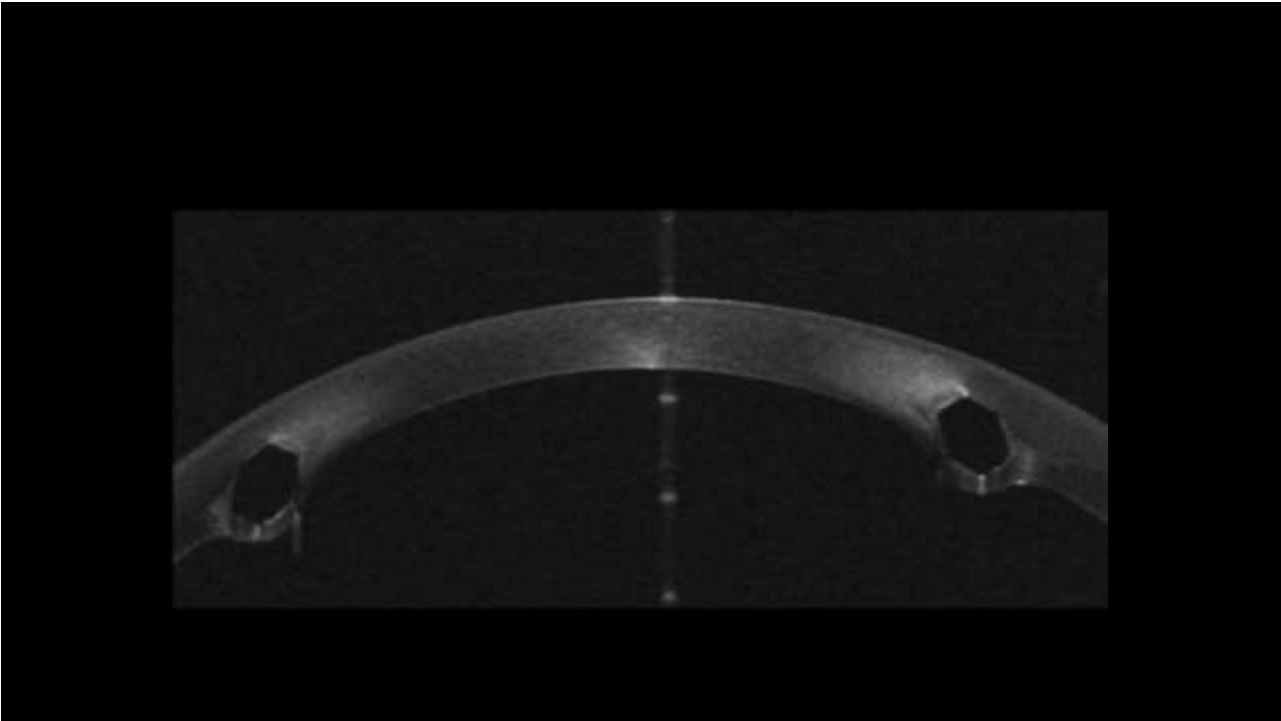
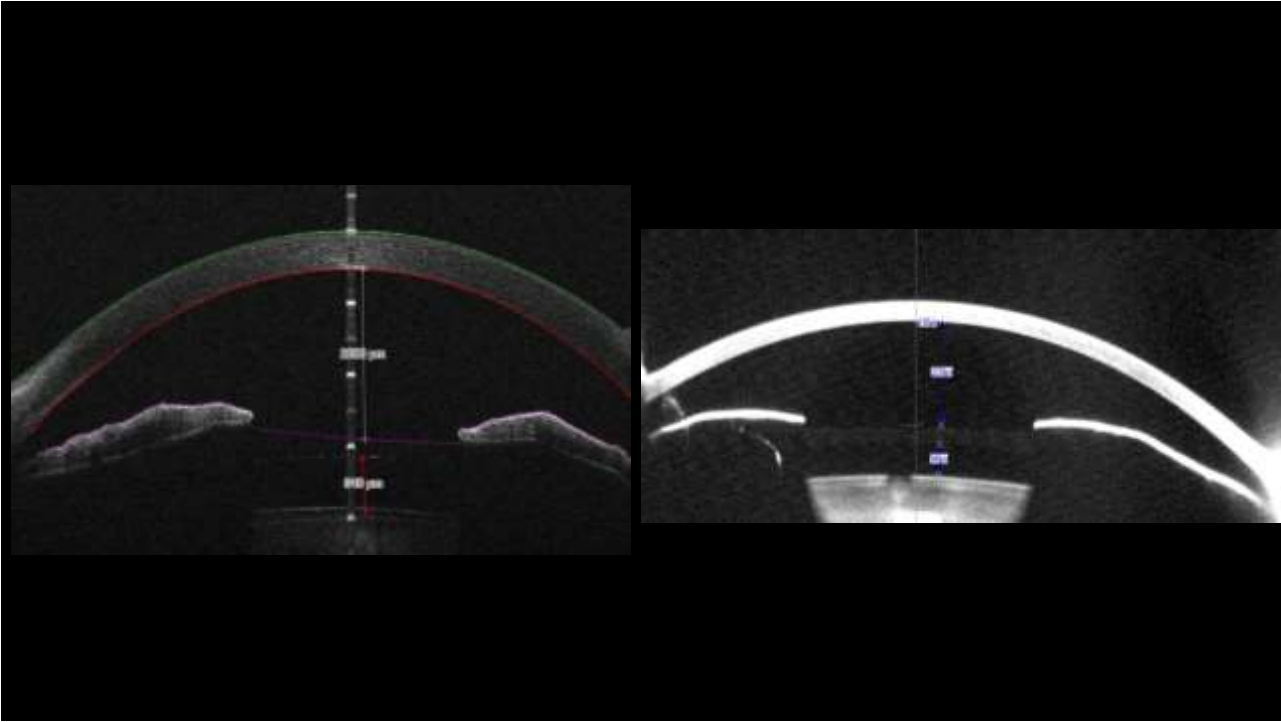


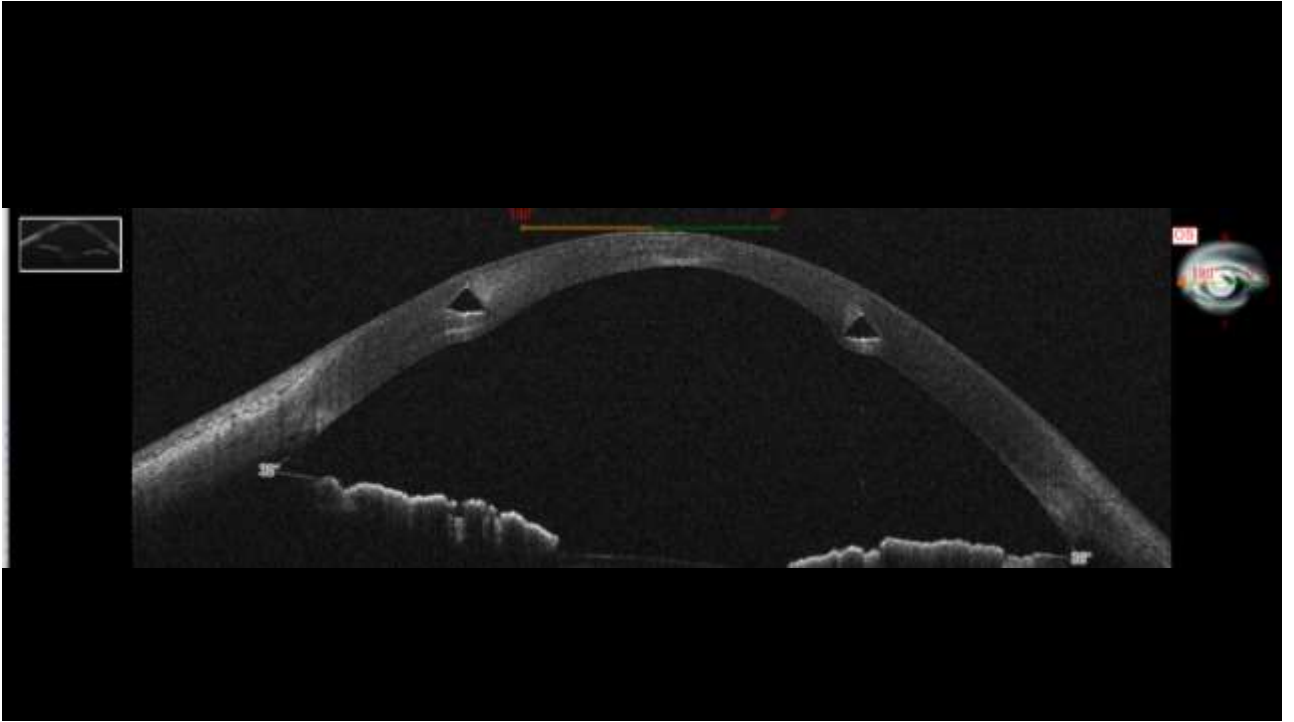
P-IOL Screening



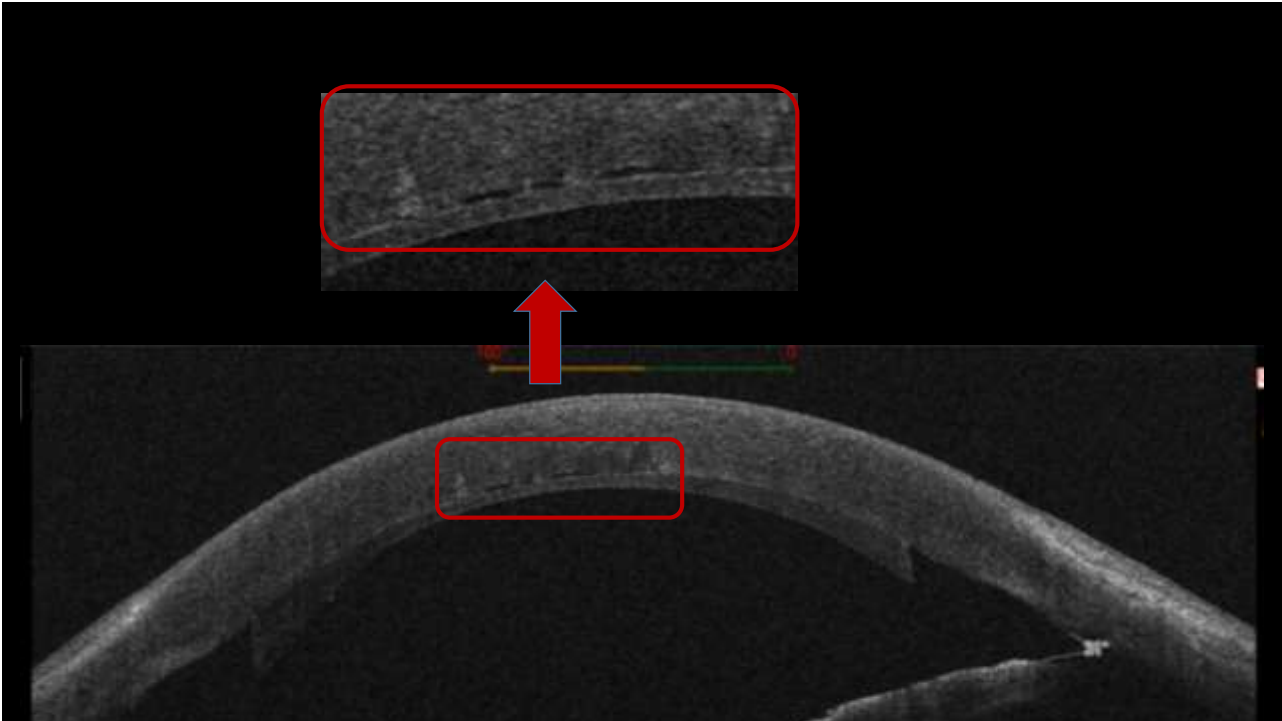
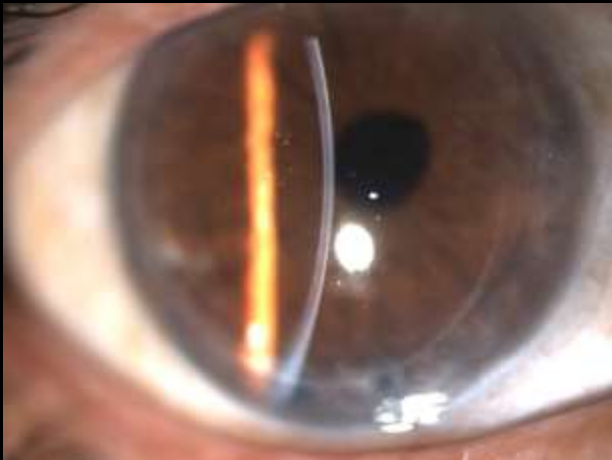...+ CLR + SS-SS + AC Angle

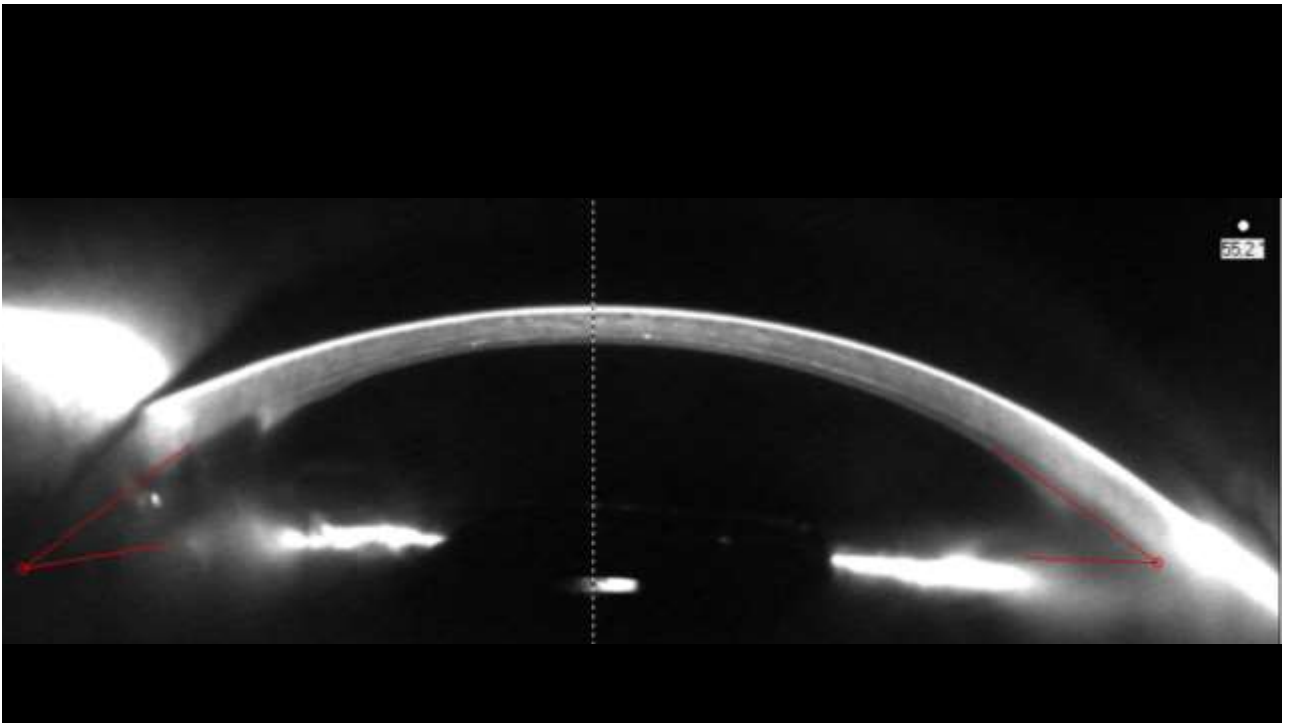
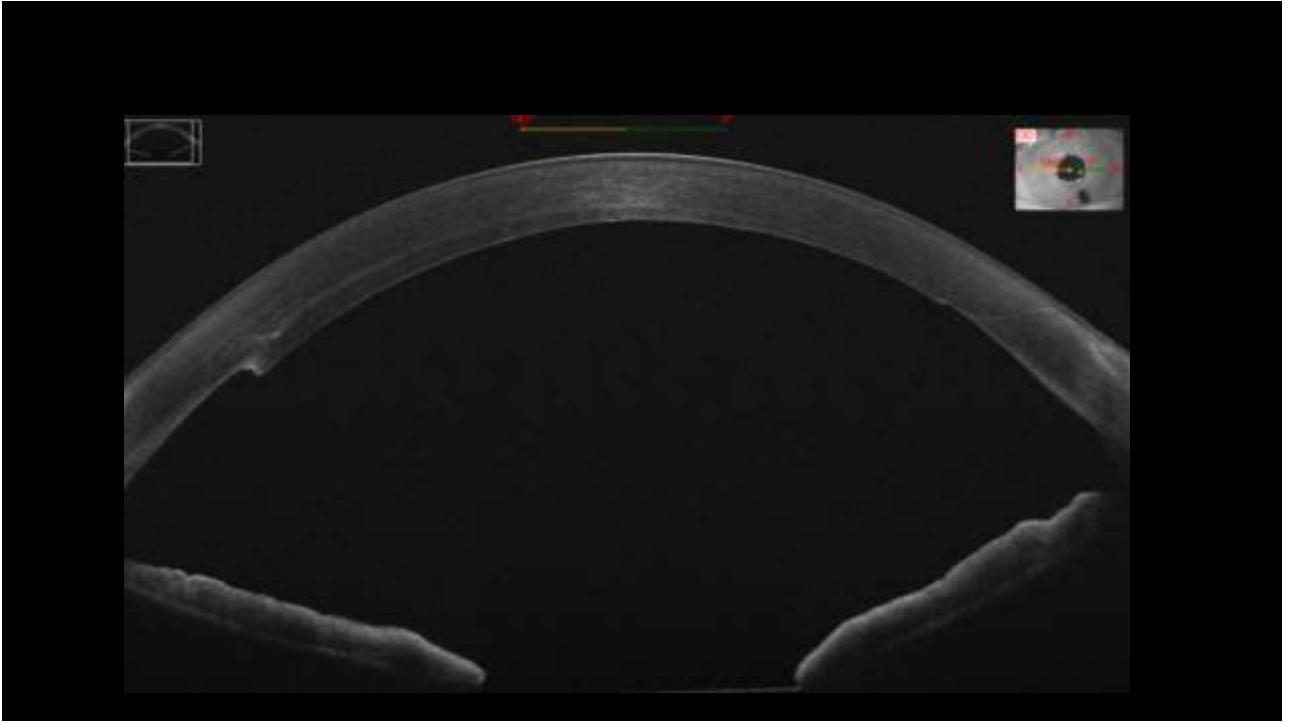




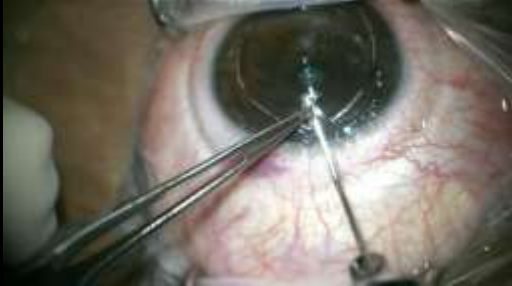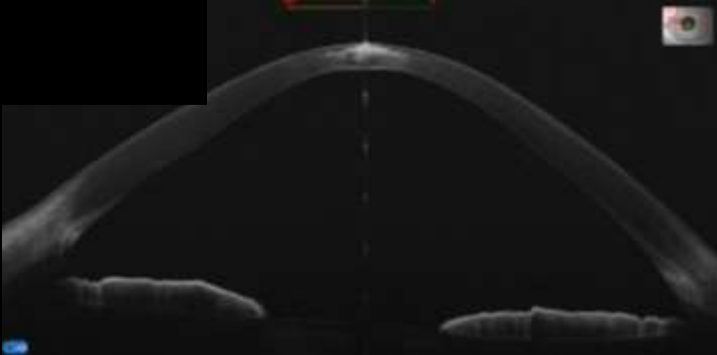


Lamellar Corneal Surgery



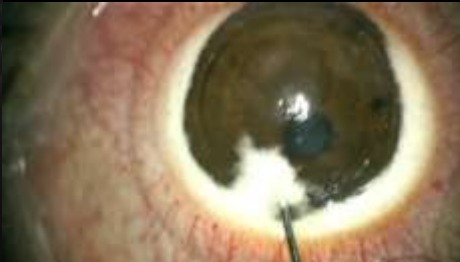

DALK Surgery

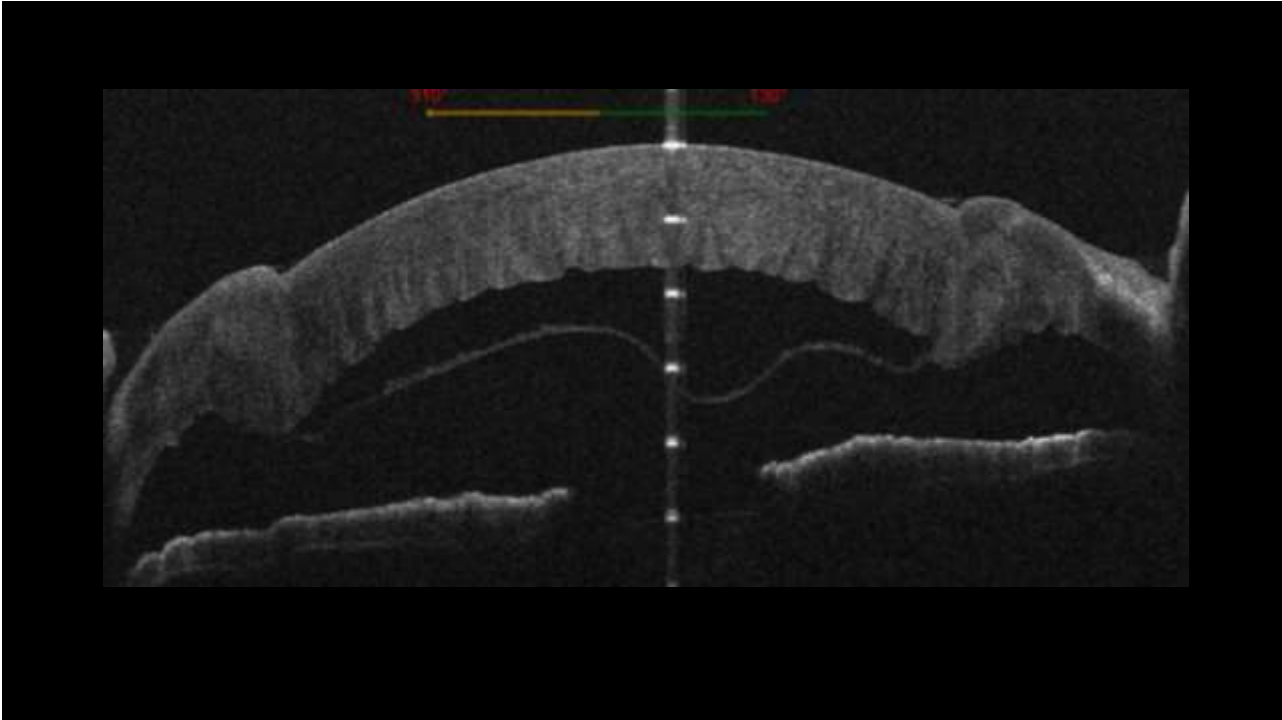


Alaa Eldanasoury, 2018

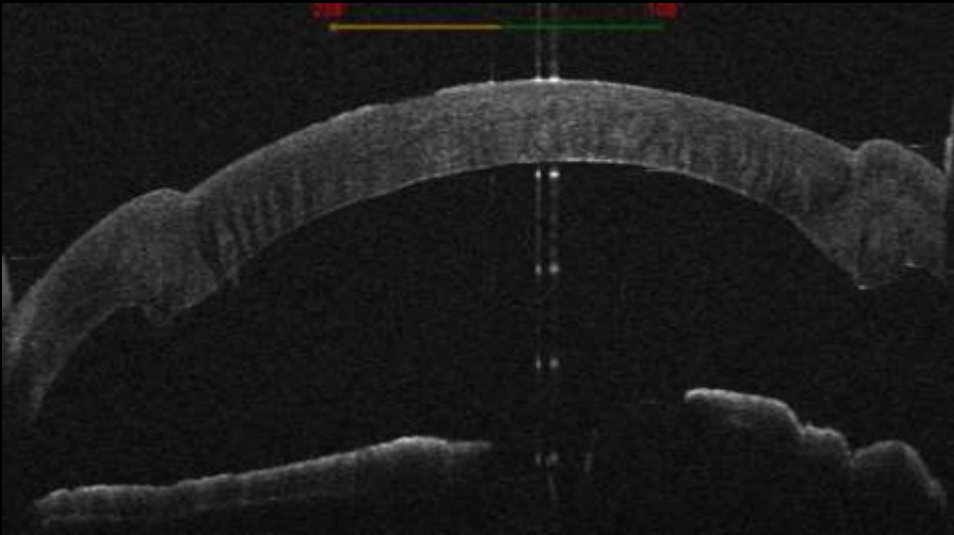
DALK Surgery

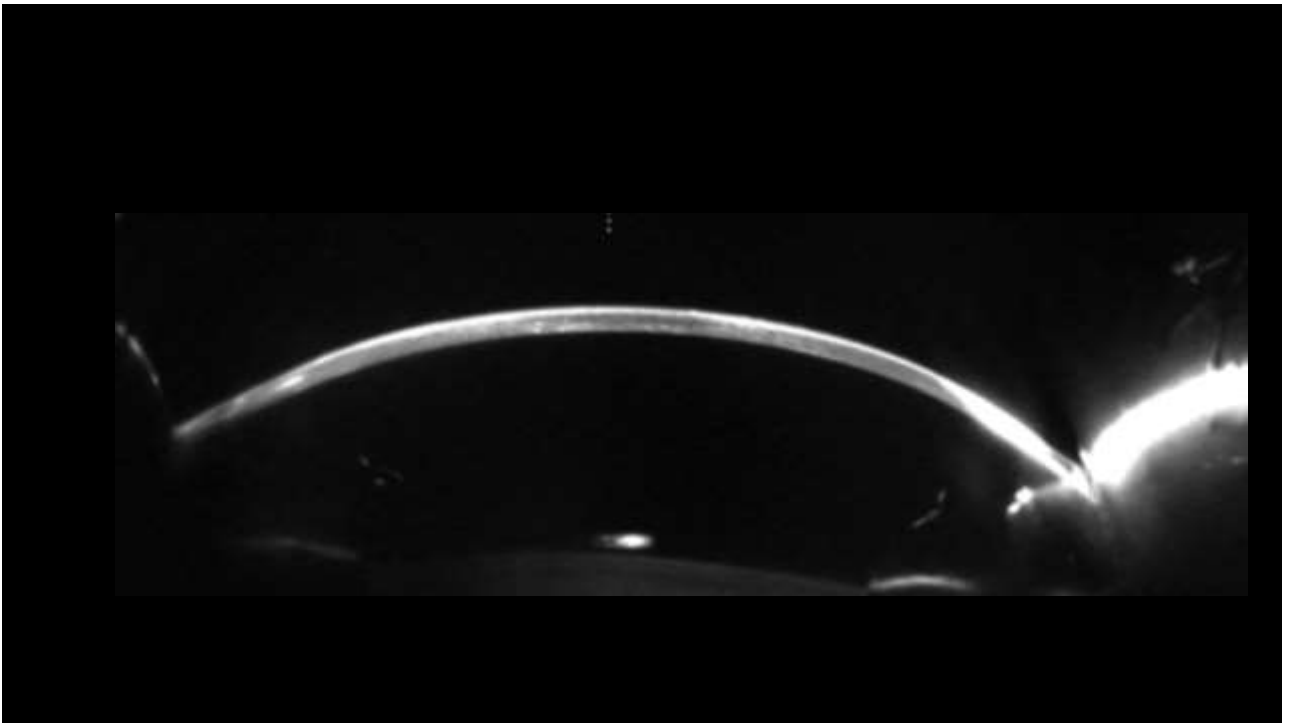
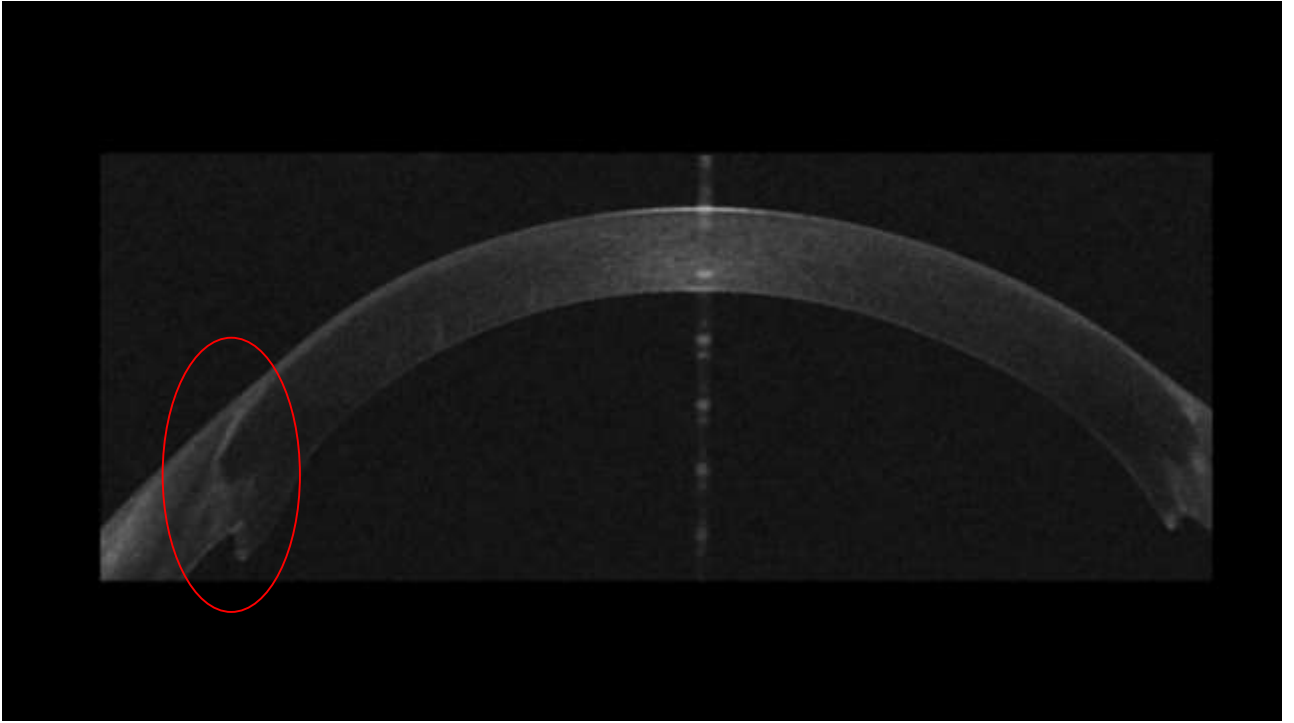


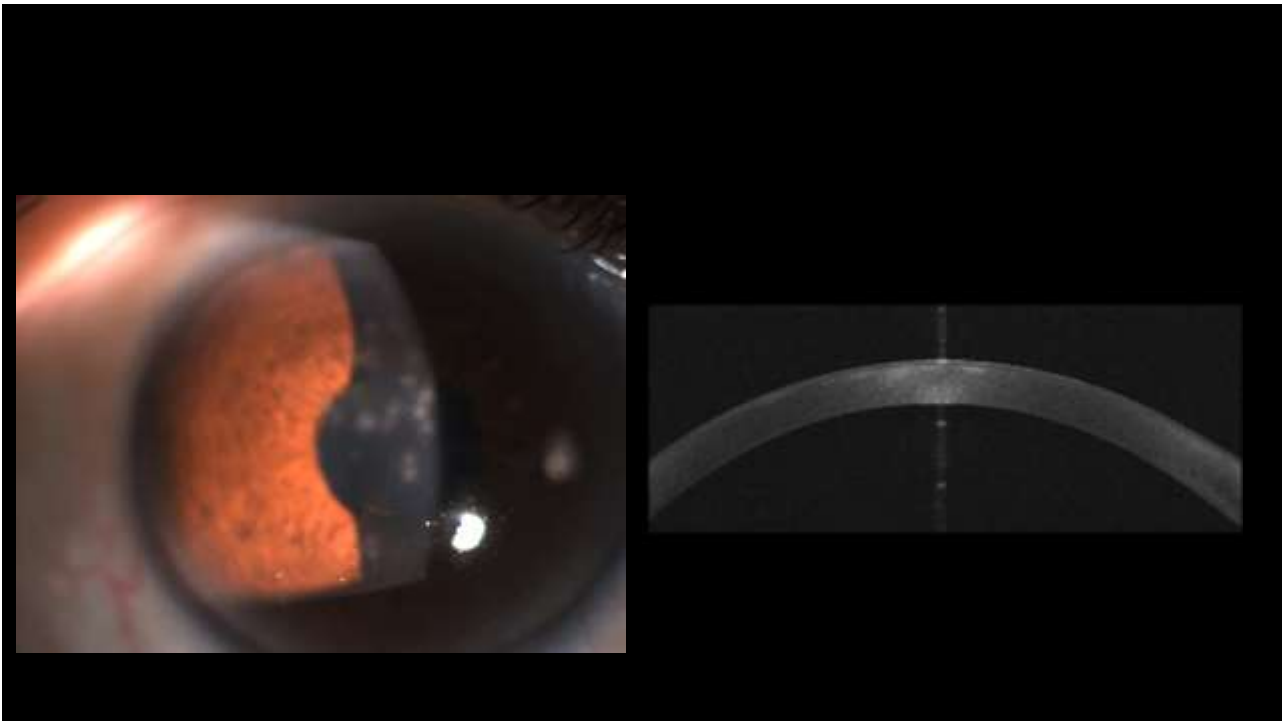
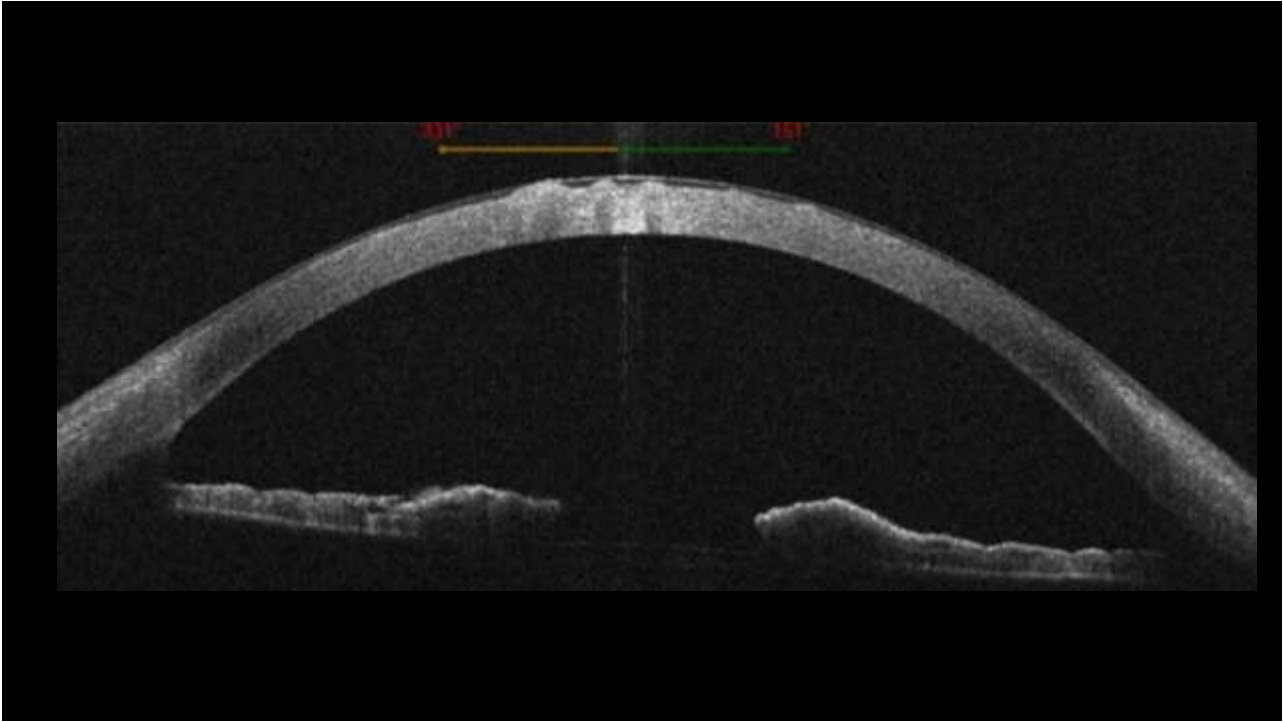
Alaa Eldanasoury, 2018



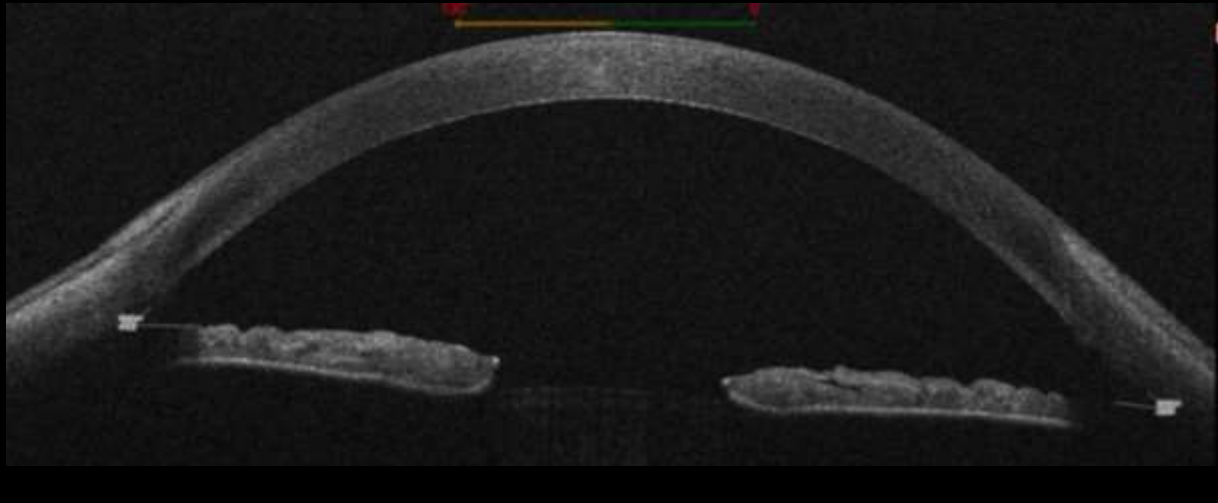
Post air injection







Fuch's; DMEK vs PKP



Reliability of Corneal and Anterior Chamber Measurements

| | Placido + AS-OCT | Scheimpflug |
|--|------------------|-----------------------|
| Anterior surface assessment | Yes | Less reliable |
| Posterior surface assessment | Yes | Only in clear corneas |
| Corneal thickness map | Yes | Only in clear corneas |
| Angle, SS-SS, CLR, P-IOL | Yes | Less reliable |
| Epithelial map | Yes | No |
| Post LASIK / SMILE / ICRS measurements | Yes | No |
| Corneal pathology / Post Corneal Surgery | Yes | No |

Placido + OCT is The Future

Thank YOU!

