

# Custom made Iris Prosthesis

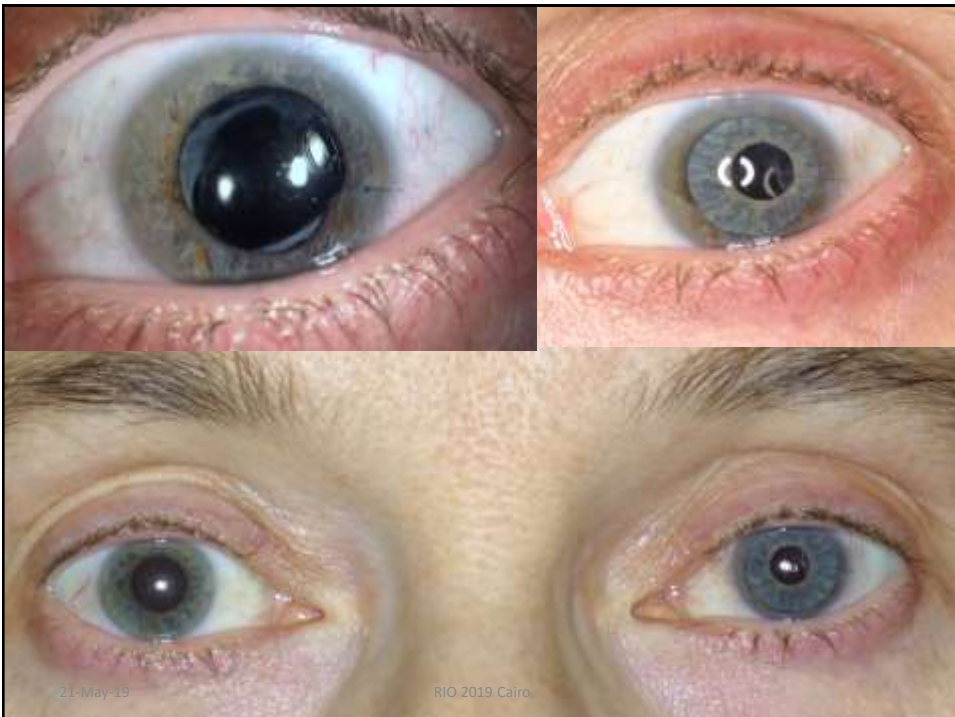Surgical techniques

University Eye Hospital

Ljubljana

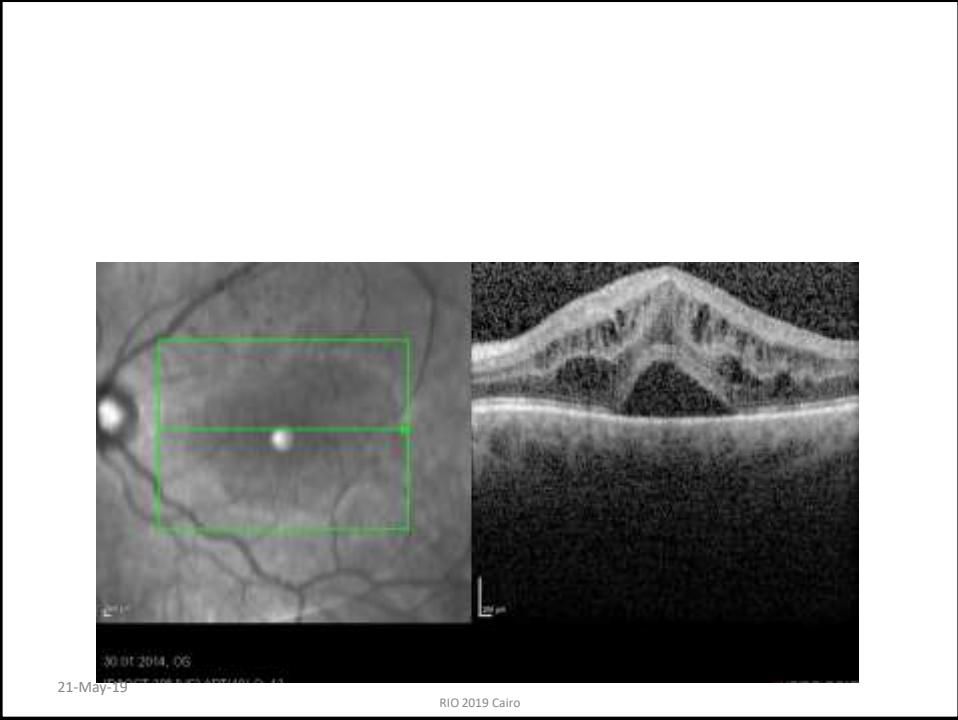
Vladimir Pfeifer

[www.okc-pfeifer.si](http://www.okc-pfeifer.si)



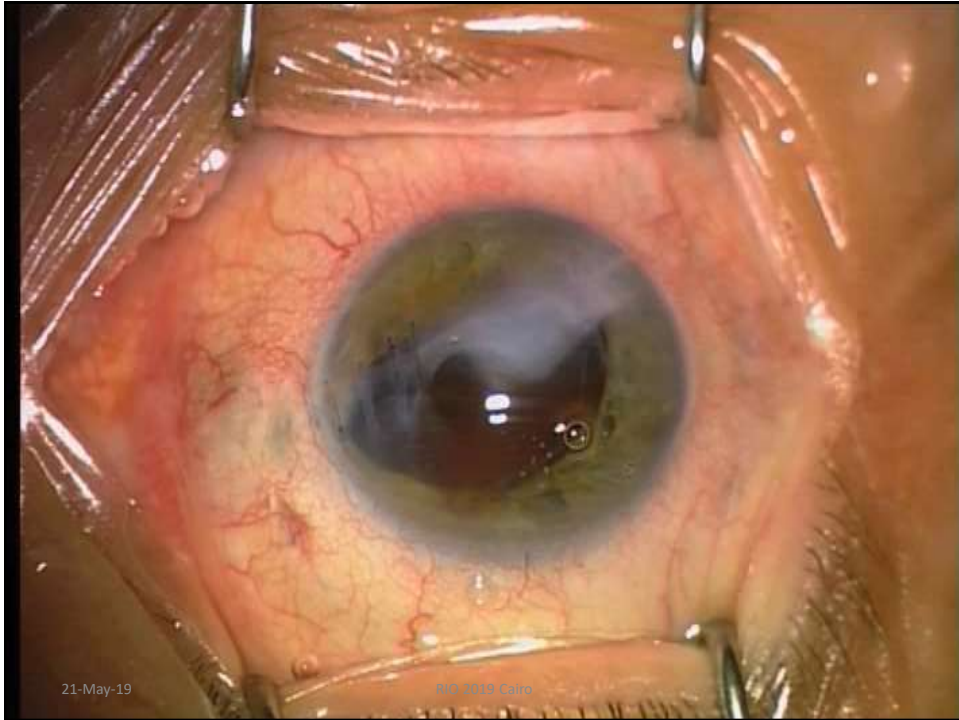
21-May-19

RIO 2019 Cairo

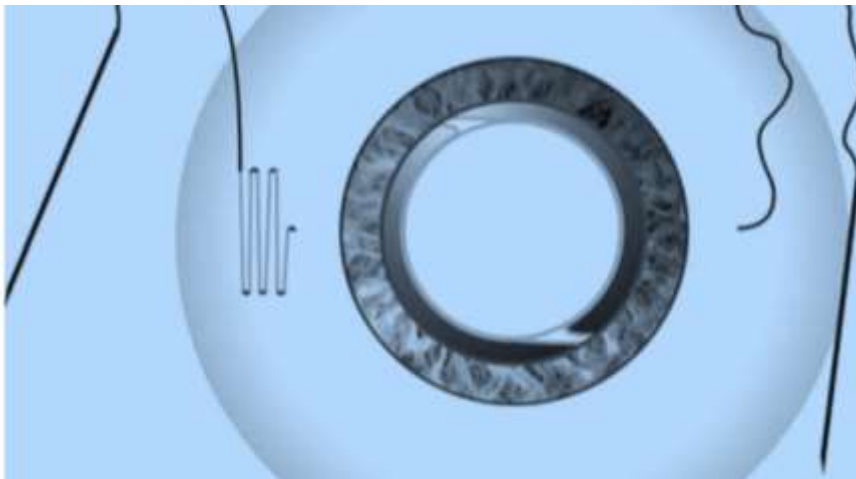

### Artificial Iris Floating Suture Technique





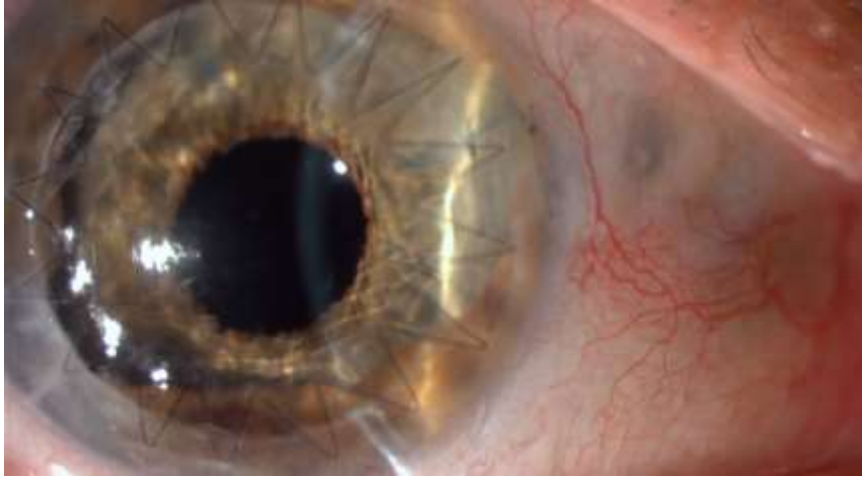
## Peter Szurman Zig Zag suture



21-May-19

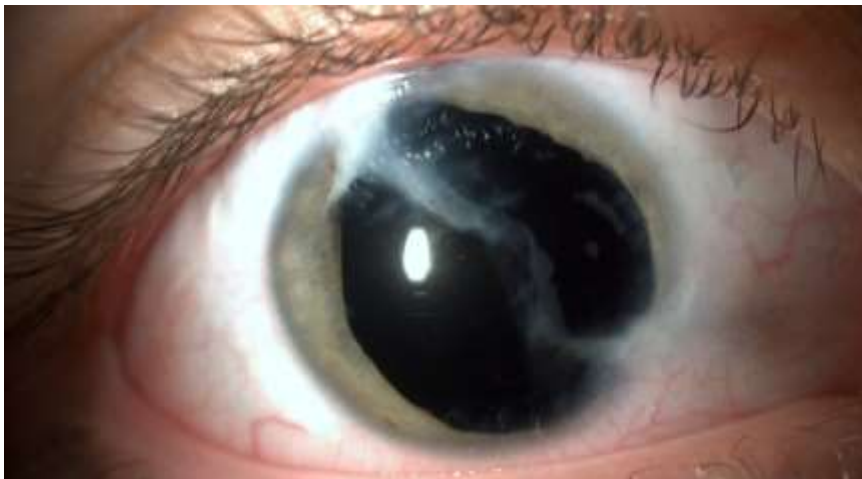RIO 2019 Cairo

VA – 3.25/125 = 0.63  
VA CL = 1.0



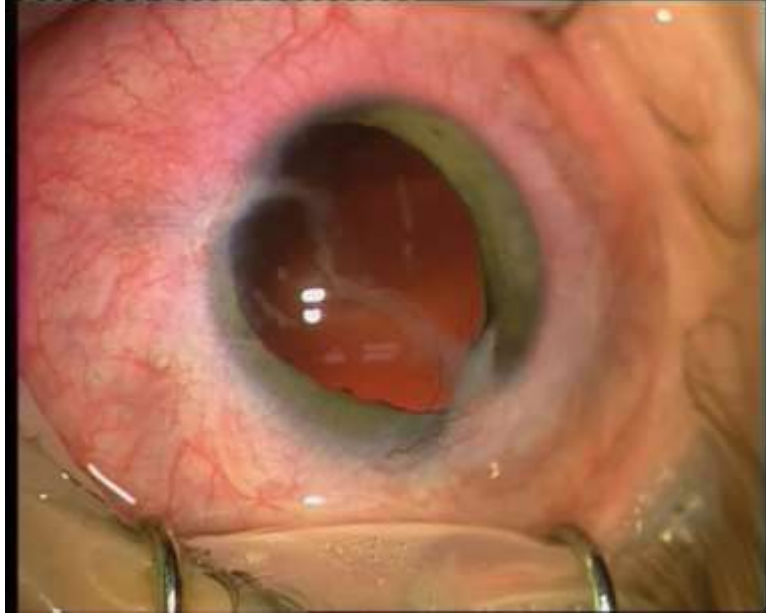
21-May-19

RIO 2019 Cairo



21-May-19

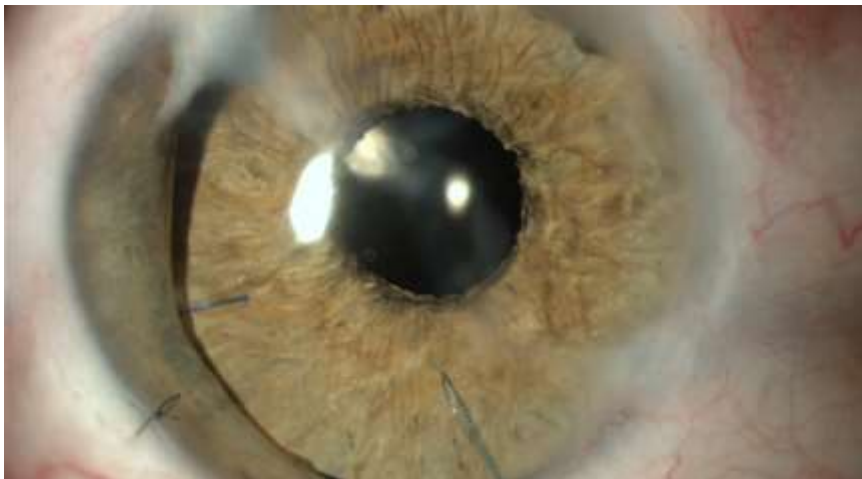
RIO 2019 Cairo



21-May-19

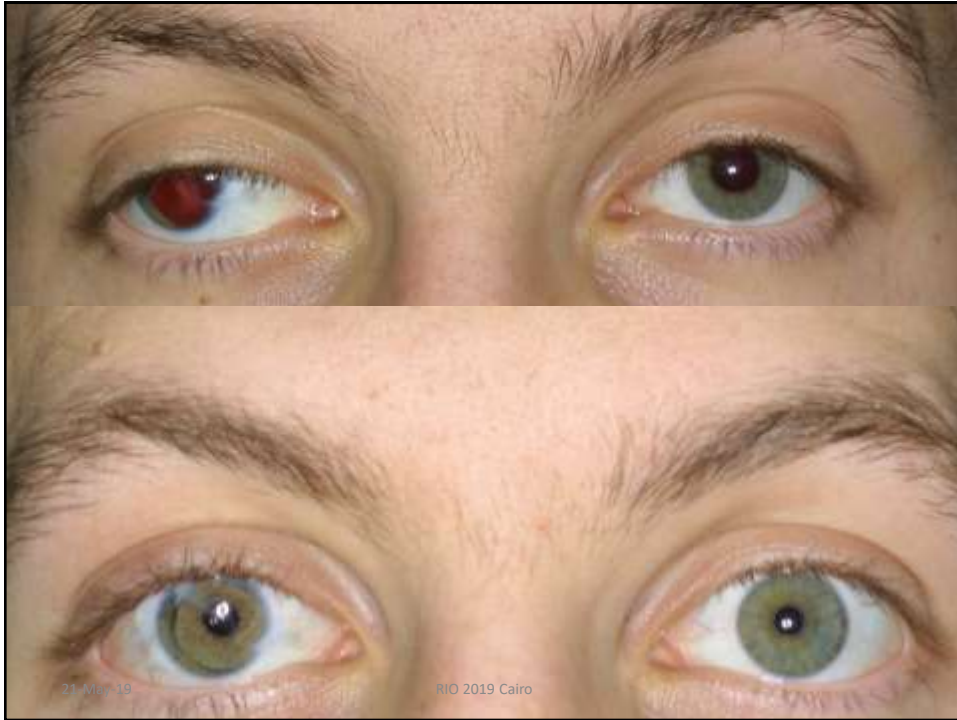RIO 2019 Cairo

$VA -1.0 = 0.32$

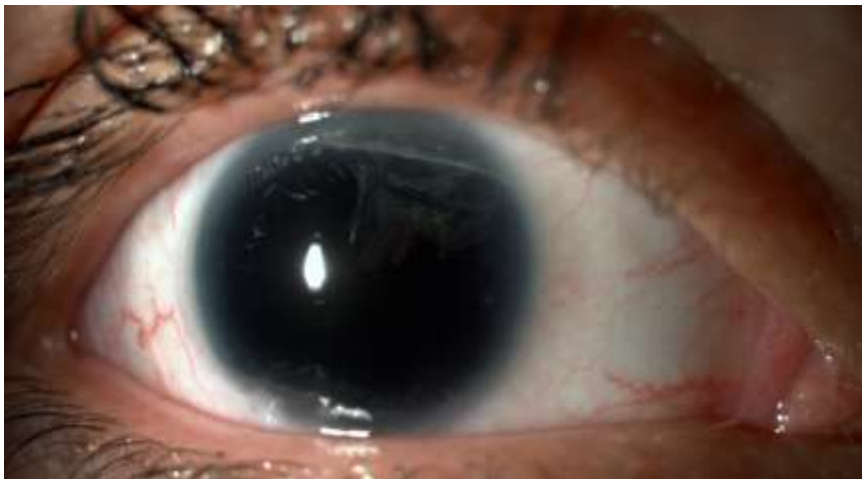


21-May-19

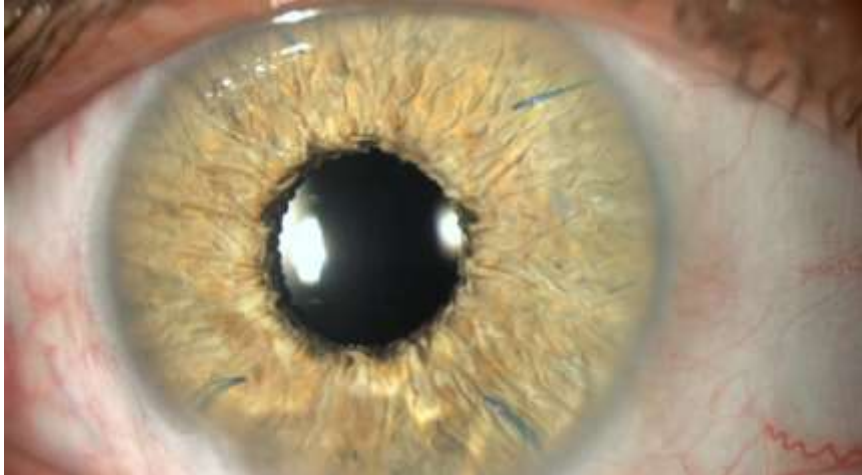RIO 2019 Cairo



## Aphakia, traumatic aniridia



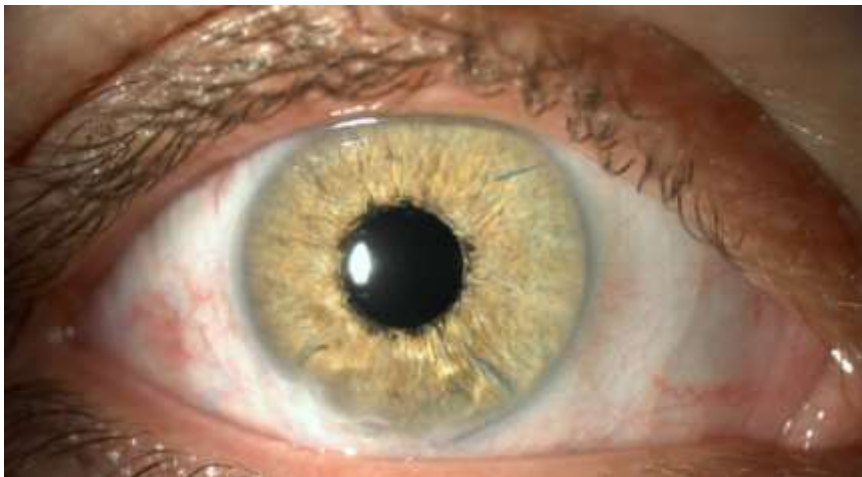




21-May-19

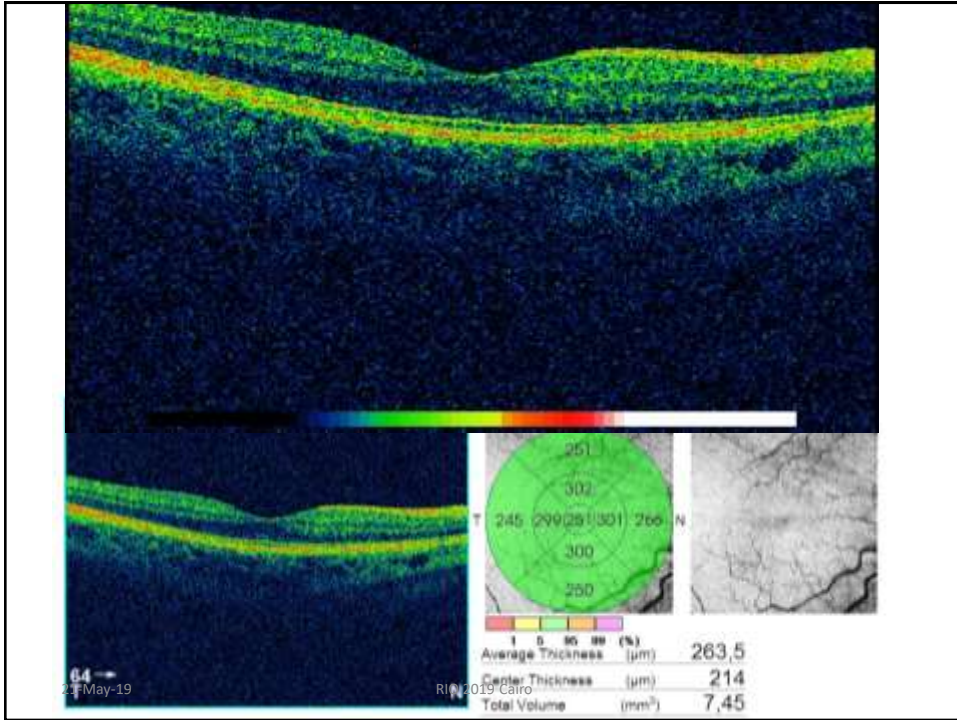
RIO 2019 Cairo

$$VA -1.0 -1.0/65 = 1.0$$



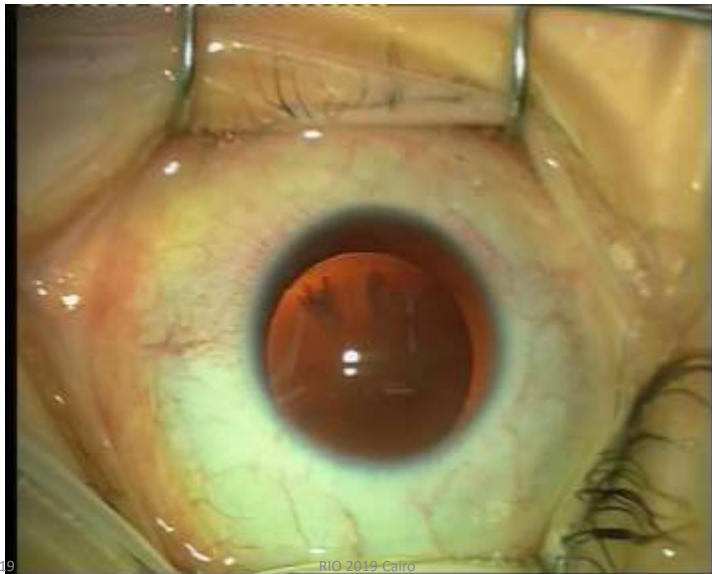
21-May-19

RIO 2019 Cairo

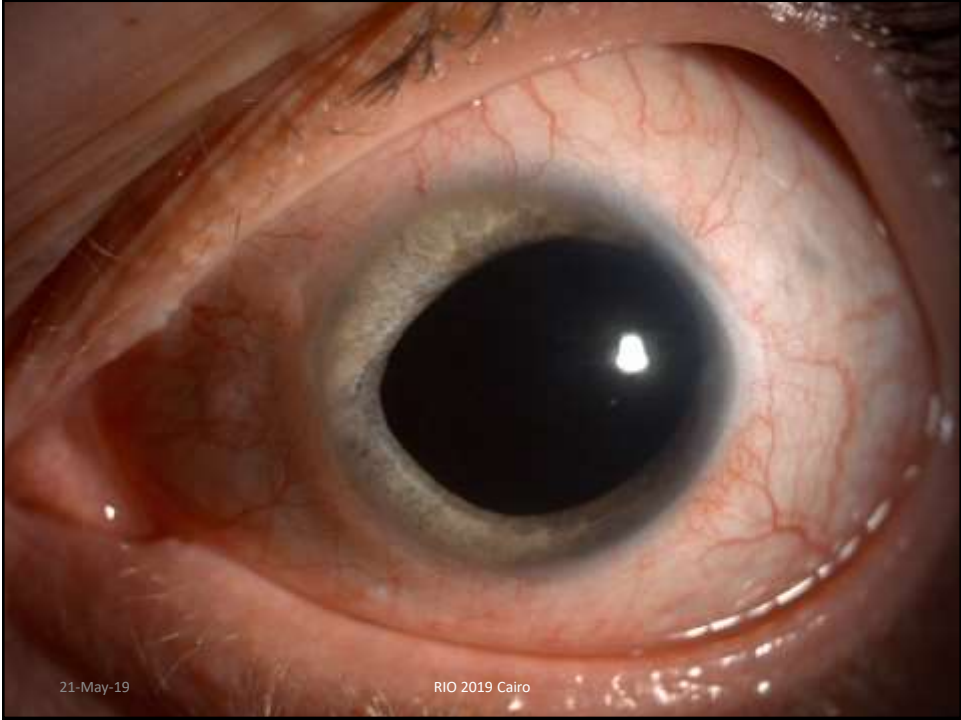


### Congenital Aniridia

VA = 0.2

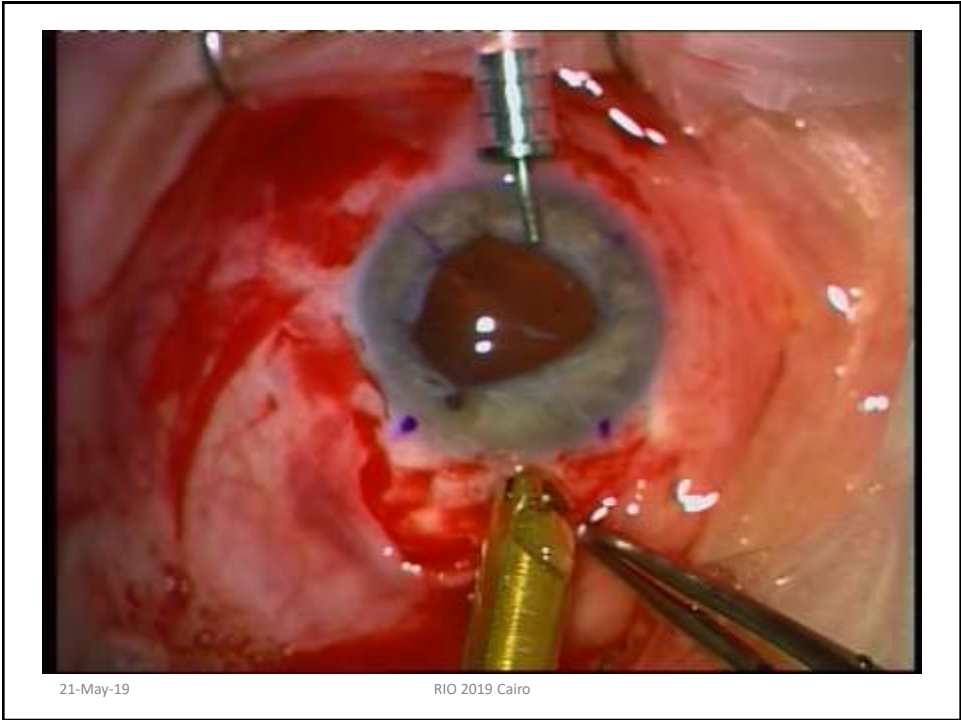






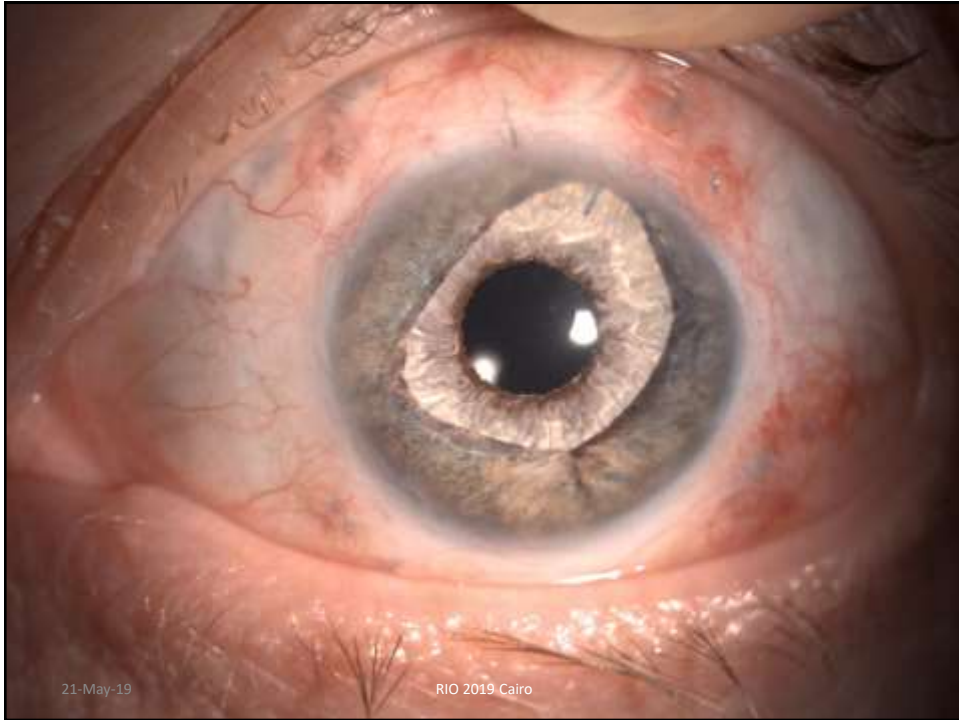
21-May-19

RIO 2019 Cairo

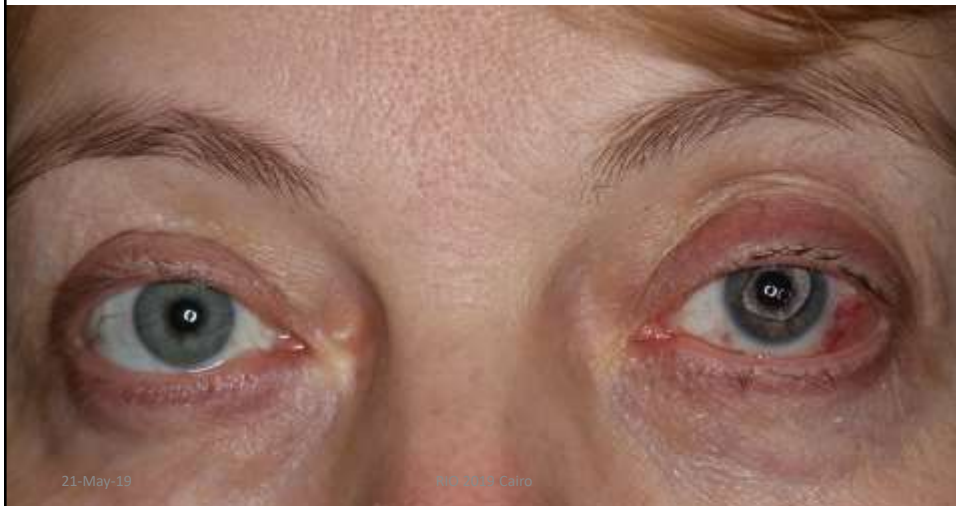

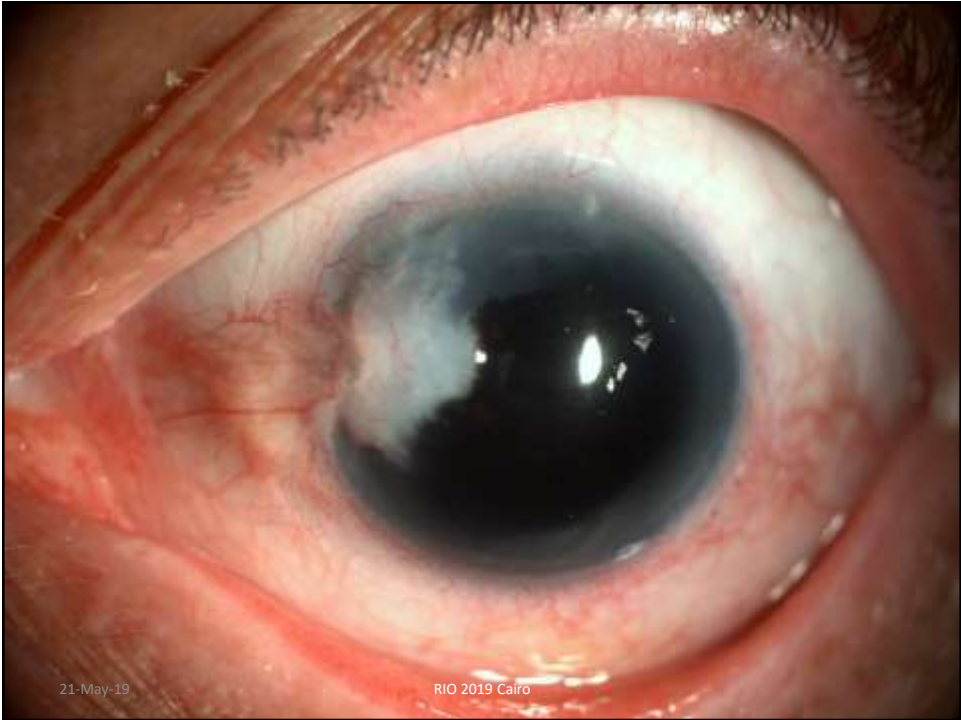
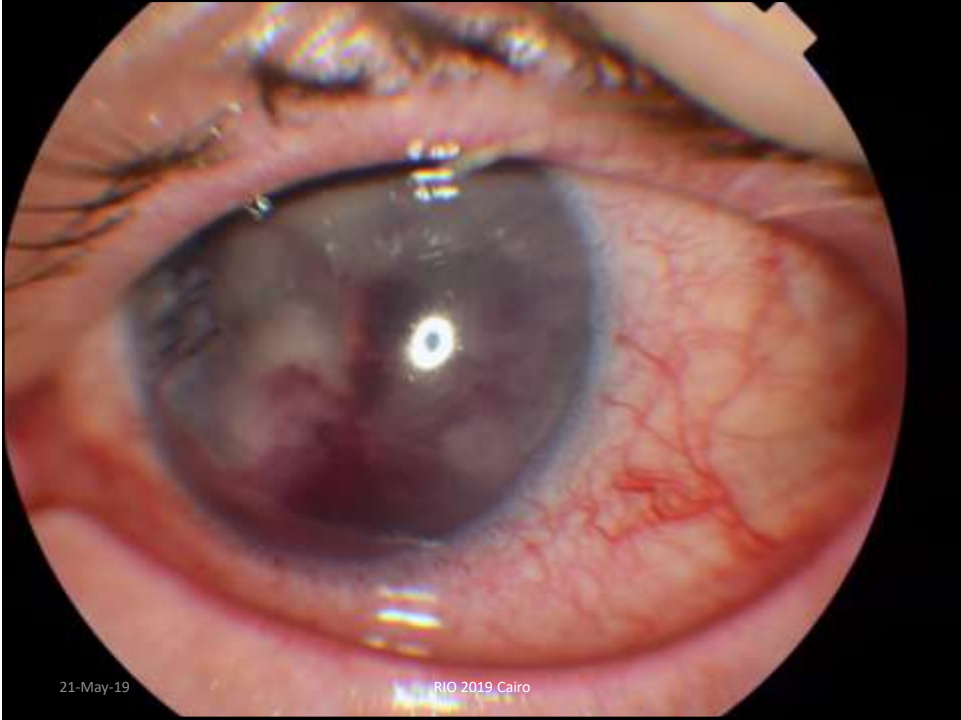21-May-19

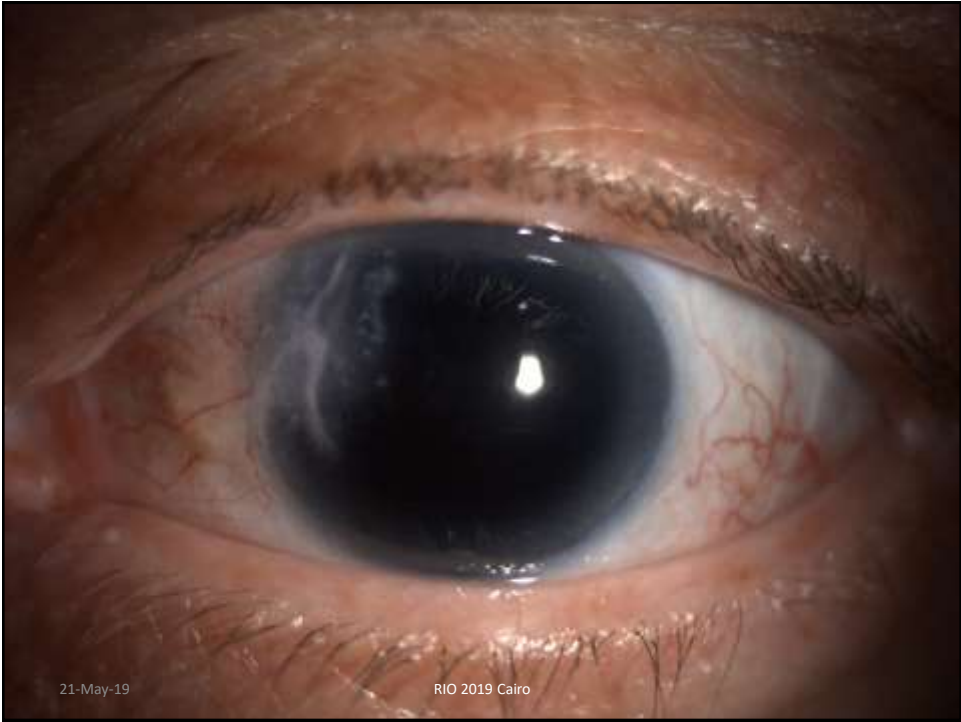RIO 2019 Cairo



1 week after surgery







21-May-19

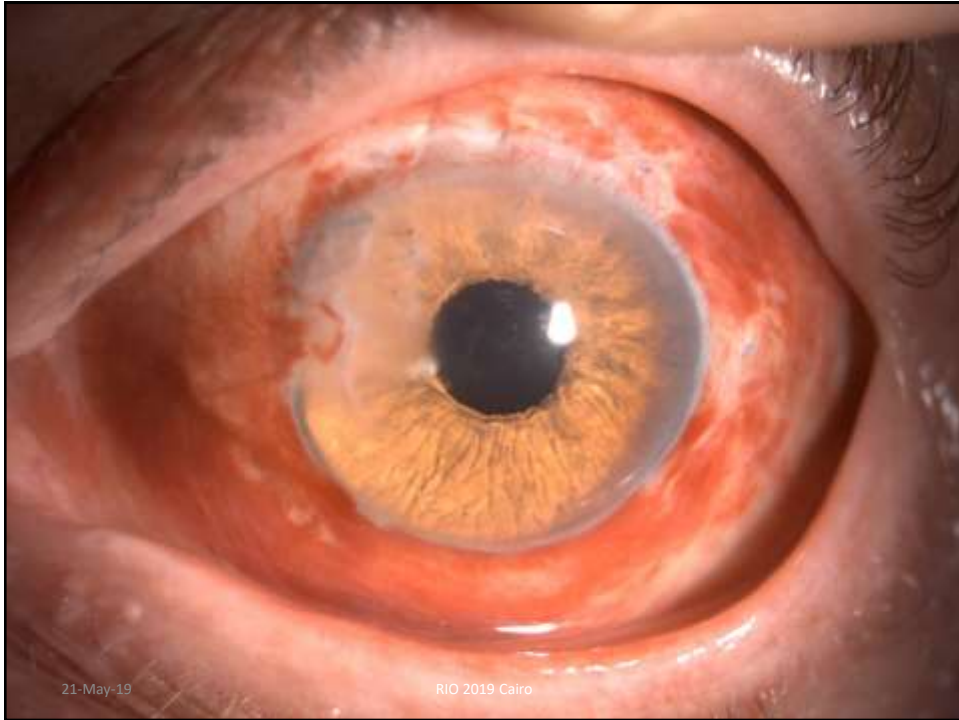
RIO 2019 Cairo



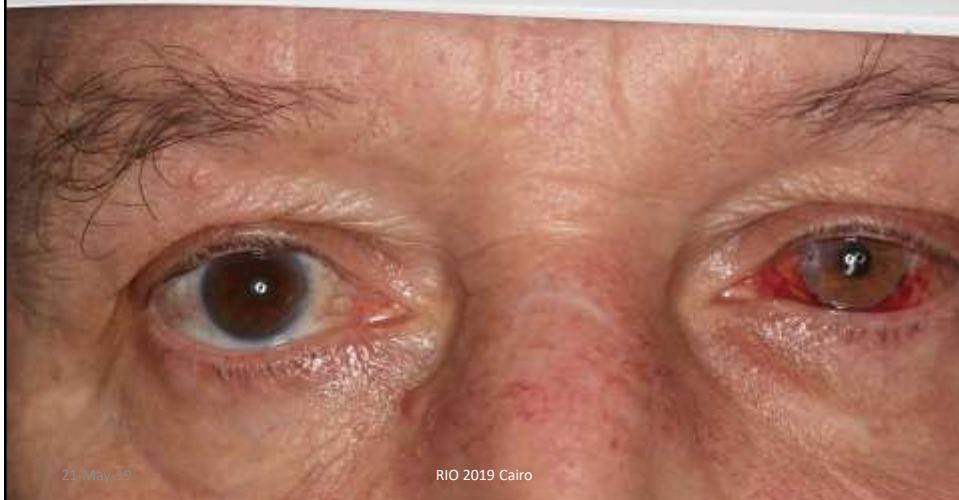21-May-19

RIO 2019 Cairo

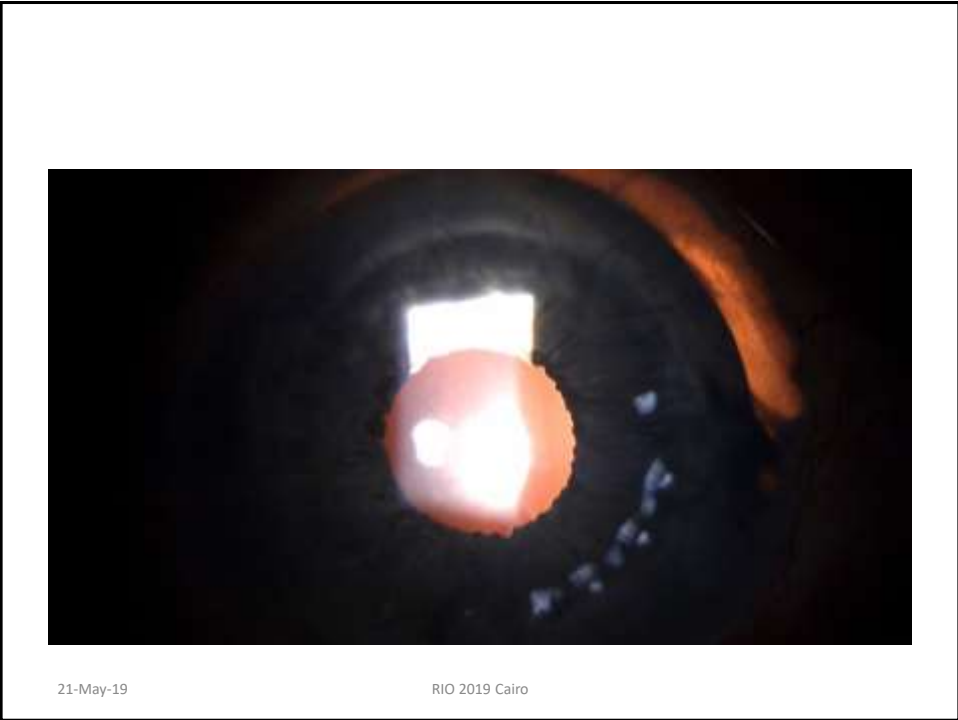
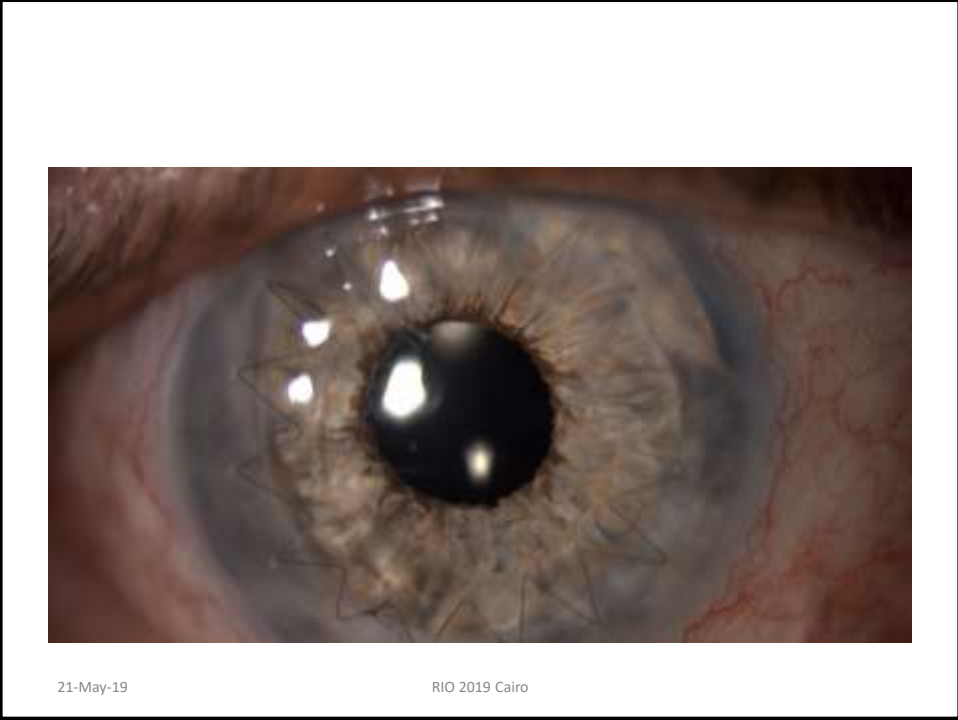


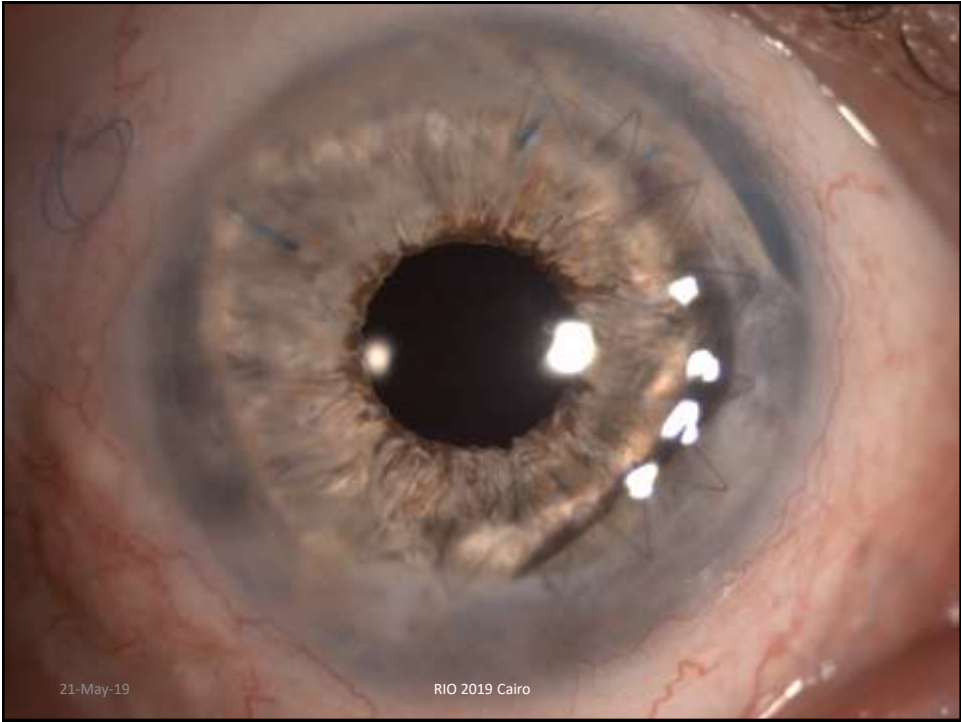


1 week post op



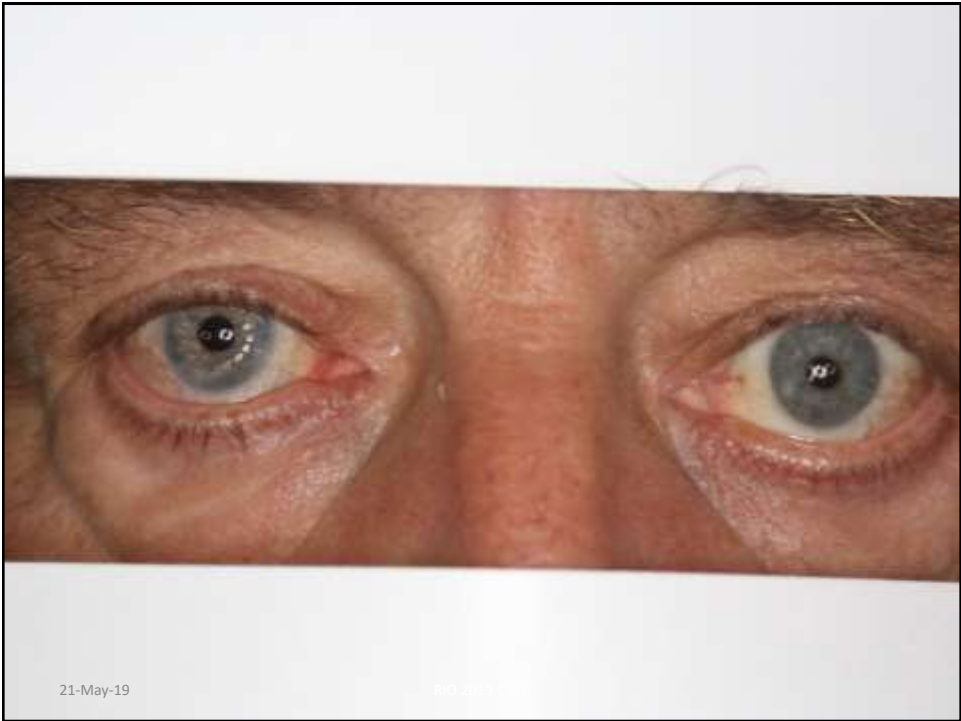





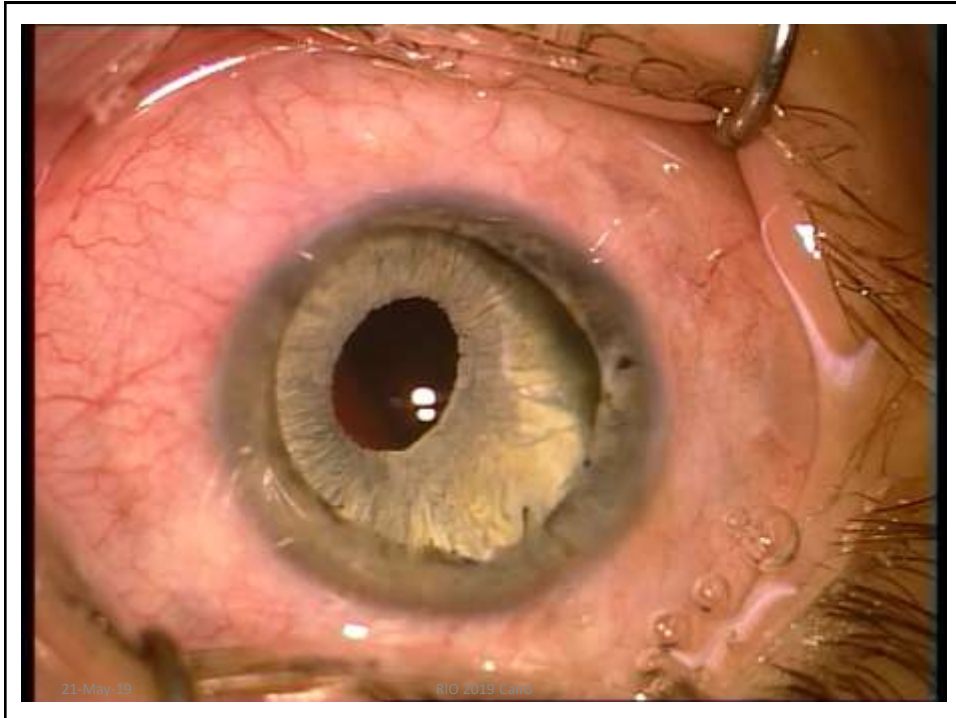
21-May-19

RIO 2019 Cairo



21-May-19

RIO 2019 Cairo



- There should not be any contact of the AI to the ocular tissue

# Thank You

21-May-19

RIO 2019 Cairo