





**CLINICA
REMENTERIA**

NEW TRENDS IN THE TREATMENT OF OCULAR
SURFACE (SESION 4)
Dr. Fco. Javier Hurtado Ceña
Dr. Agustín Moreno Salgueiro
25th of January, 2018


**NEW TRENDS IN THE TREATMENT
OF OCULAR SURFACE**

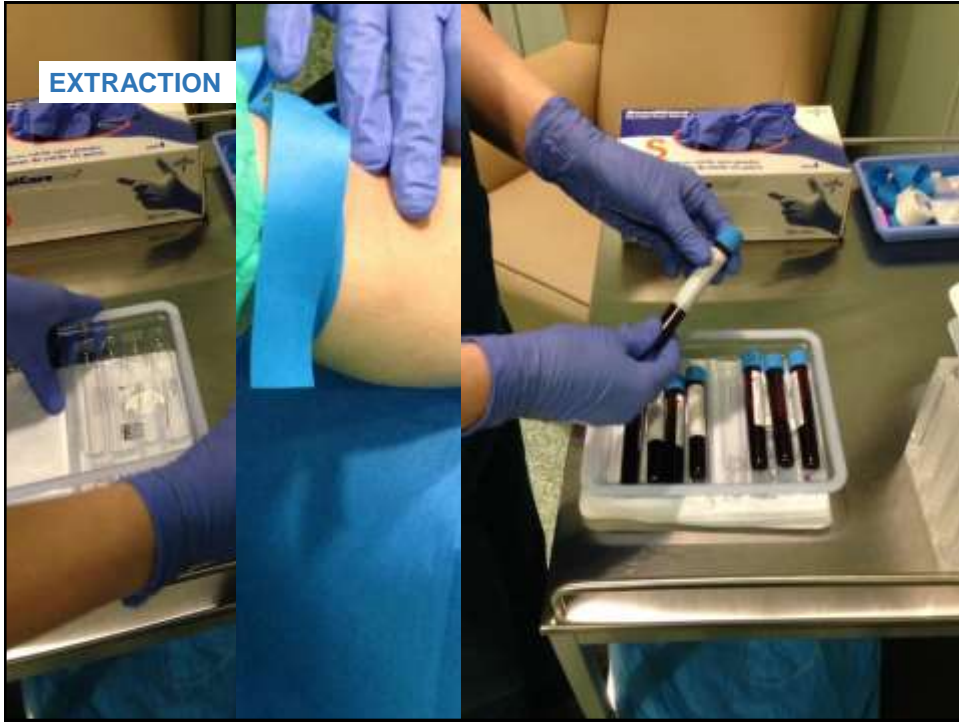

**CLINICA
REMENTERIA**

OPTIONS IN REGENERATIVE MEDICINE:

- ◆TISSUES AND ARTIFICIAL ORGANS TRANSPLANTATION
- ◆STEM CELLS
- ◆BIOLOGICAL OR CHEMICAL INDUCTION:
 1. CACICOL®
 2. NEURONAL GROWTH FACTOR (NGF)
 3. PLASMA RICH IN GROWTH FACTOR (ENDORET®)
 1. Type of plasm rich in platelets without leucocytes and with the possibility of being used at normal temperature for 72 hours





AUTOVACCUM

CLINICA REMENTERIA

Vt

Plasma rich in growth factors

Serie Blanca

Leucocytes

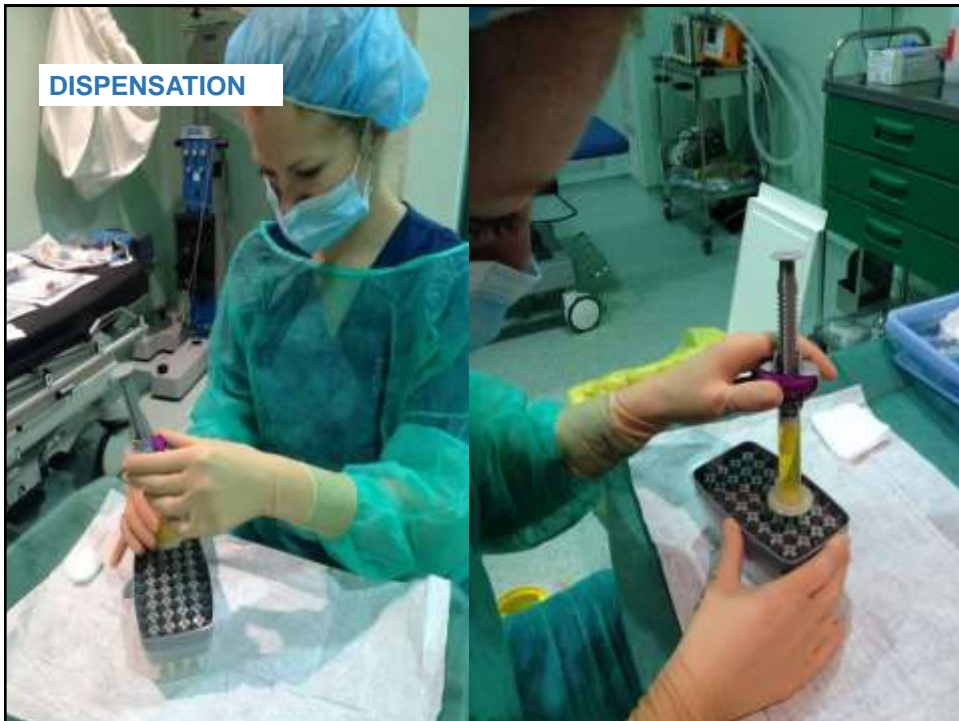Serie Roja

Red cells

Tubo 10 ml

Dr. E. Abela





NEW TRENDS IN THE TREATMENT OF OCULAR SURFACE



- We finally get a Platelets Rich Plasma free of leucocytes that patient can use at normal temperature.
- Higher cost than other blood derivatives.
- It is a “closed technique” (warranty of quality given from AEMPS/EAMSP)
- It can be made in any place with a minimum hygiene measures.
- Independence.
- We are sure that the composition of the final product is the correct one.



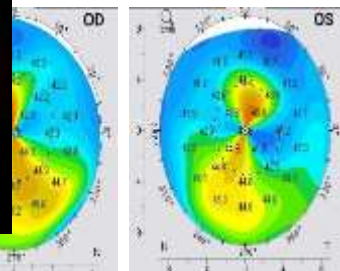
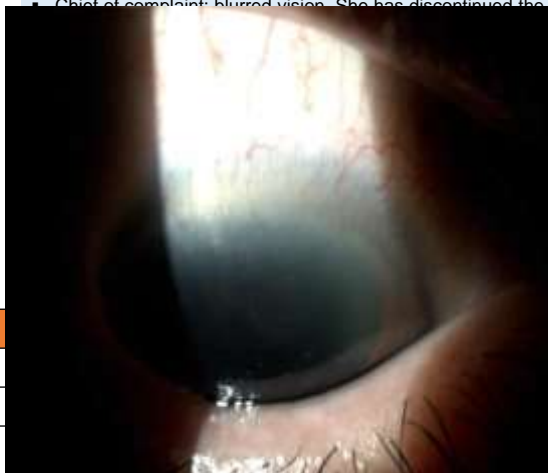PATIENT 1



- Female, 59 years old with myopia and use of contact lenses for years.
- Chief of complaint: blurred vision. She has discontinued the use of contact lenses for three

...ects central cornea.

Axis	VA
5°	0,6
60°	0,6



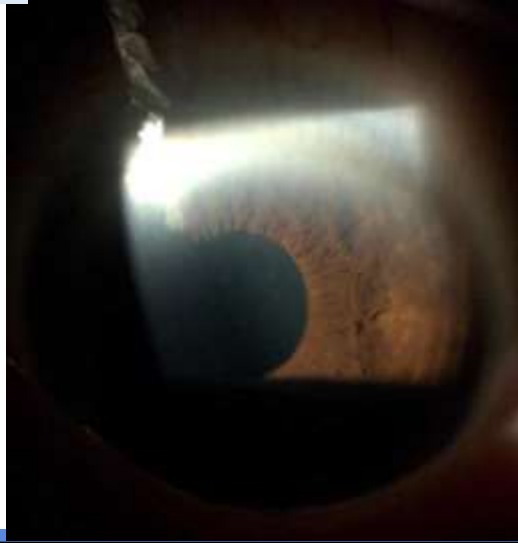
PATIENT 1



- 3 months after the treatment with PRGF

GLAS SES	Sphere	Cylinder	Axis	VA
RE	-2,00	-1,00	5º	0,6
LE	-2,75	-0,75	160º	0,6

	Sph.	Cyl.	Axis	VA
RE	-1,50	-1,00	5º	1,0
LE	-2,00	-0,75	160º	1,0



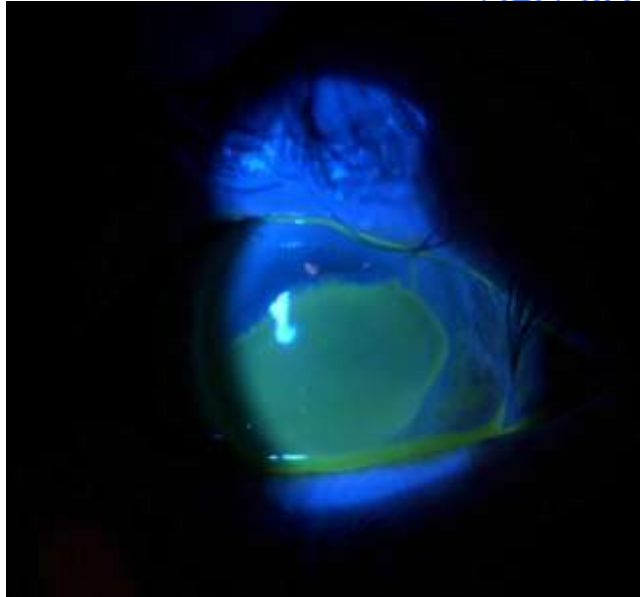
PATIENT 2



- Male, 74 years old with a previous cataract surgery (2008) and an episode of herpetic keratouveitis in the right eye.
- Chief of complaint: blurred vision and redness in the right eye for three weeks. Epithelial defect for three weeks (metaherpetic ulcer).
- Treatment:
 - Valaciclovir 1 g/12 hours
 - Ciprofloxacin 3 times a day
 - Artificial drops and gel several times a day
 - Autologous serum 3-4 times a day
- Ophthalmological findings: central corneal ulcer with Descemet's folds.

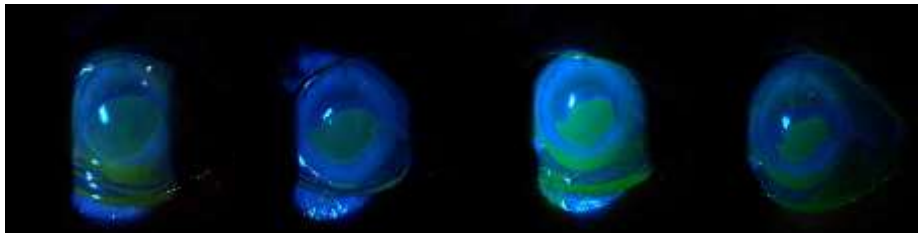
PATIENT 2

CLINICA
REMENTERIA



PATIENT 2

CLINICA
REMENTERIA

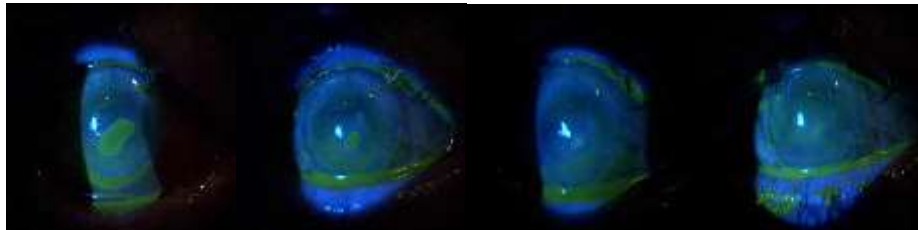


2 days

1 week

2 weeks

3 weeks



4 weeks

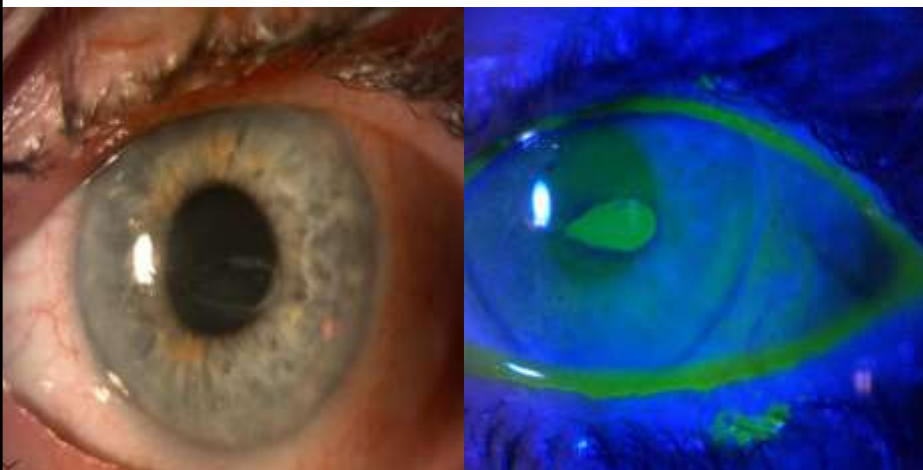
6 weeks

8 weeks

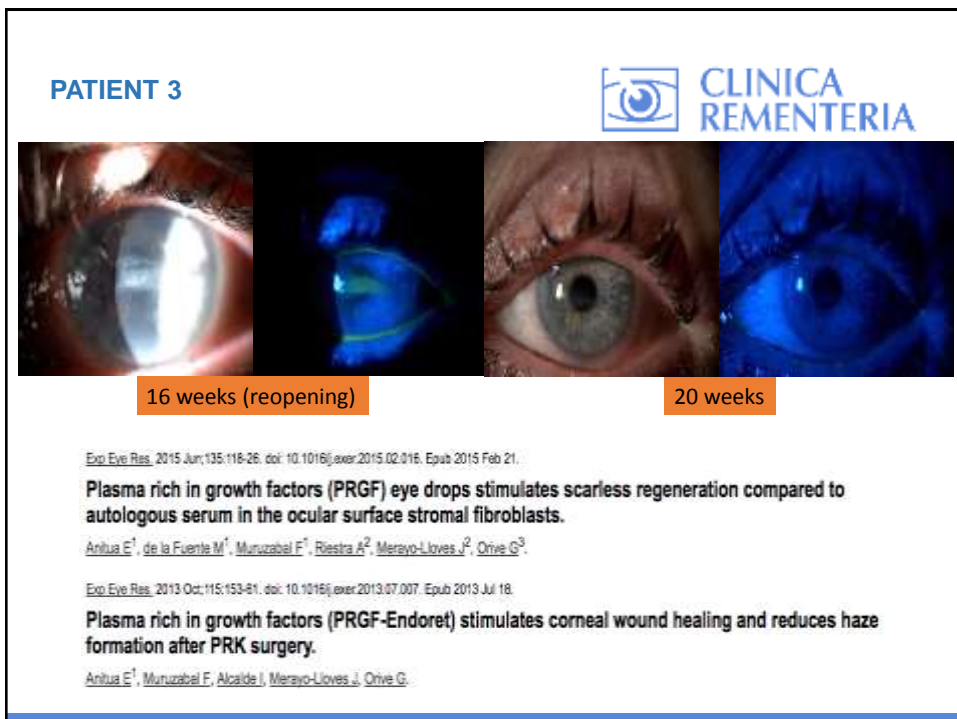
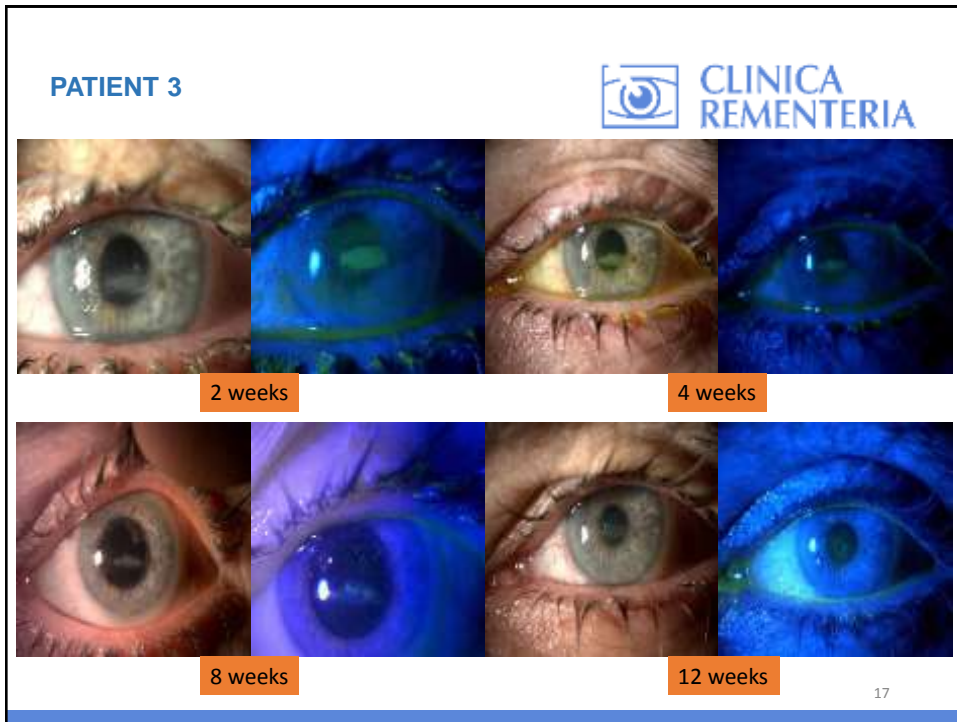
10 weeks

PATIENT 3

- Male, 64 years old with a previous cataract surgery (2007) and wide angle primary glaucoma treated with bimatoprost 0,1 mg/ml for years.
- Treated with acenocumarol (Sintrom®) due to a metallic cardiac valve.
- Retinal detachment treated with pars plana vitrectomy in the right eye (27th June, 2016) with visual acuity 0,5 on the 19th July, 2016).
- 3rd August, 2016. Chief of complaint: blurred vision in the right eye for one week.
- Ophthalmological findings: neurotrophic ulcer.

PATIENT 3

PRP 3-4 times a day
Antibiotic
Artificial drops



CONCLUSIONS



- Platelets Rich in Groth Factors (PRGF) has some advantadges over other blood derivatives:
 - It is a “closed technique” (warrantee of quality given from AEMPS/EAMSP)
 - It can be made in any place with a minimum hygiene measures.
 - Independence.
 - We are sure that the composition of the final product is the correct one.
- It can be useful in difficult cases of:
 - Corneal pannus
 - Insidious corneal ulcers

