

# Anti-VEGFs in PDR

## What Do We Know to Date?

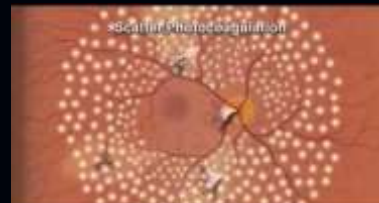**Dina Baddar** FRCS

Research Institute of Ophthalmology

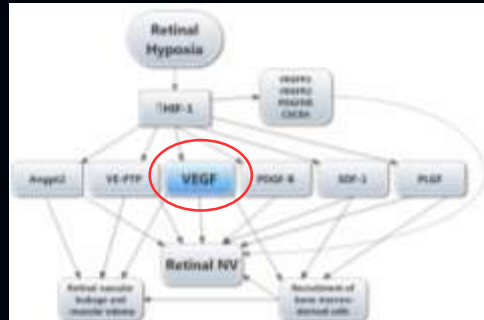
Research Institute of Ophthalmology Meeting, January 2018

## History

- 1991
- Early Treatment Diabetic Retinopathy Study
- High Risk PDR → PROMPT scatter laser
- Criteria
  - 1) NVDs  $\geq$  1/4-1/3 disc area in size or larger
  - 2) Less extensive NVD  
if vitreous or pre-retinal hemorrhaging was present
  - 3) NVEs  $\geq$  1/2 disc area  
if vitreous or pre-retinal hemorrhaging was present
- Typical Rx
  - 1500-5000 burns across
  - 1-4 treatment sessions
  - 200 $\mu$  to 500 $\mu$  in size
  - pulse duration 100 milliseconds
  - 200-250 mW of power

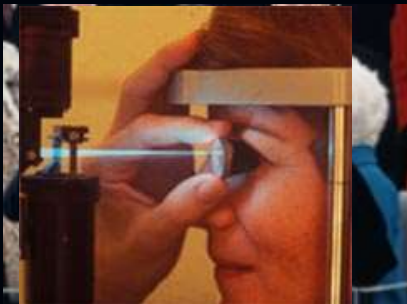


# Rationale

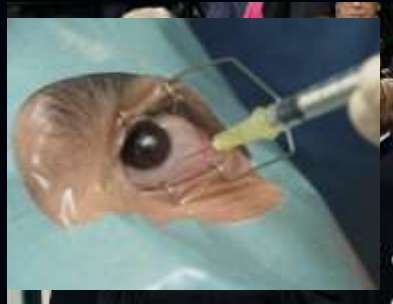

Anti-Vascular Endothelial Growth Factor Agents in the Treatment of Retinal Disease Campochiaro, Peter A. et al. Ophthalmology , Volume 123 , Issue 10 , S78 - S88

1991



2017




# What's New in 2017

Date	Article
Apr 17, 2017	FDA Approves Genentech's Lucentis (ranibizumab) for all Forms of Diabetic Retinopathy
Jan 5, 2017	FDA Approves Genentech's Lucentis (ranibizumab) for Myopic Choroidal Neovascularization
Oct 14, 2016	FDA Approves Genentech's Lucentis (ranibizumab) Prefilled Syringe
Feb 6, 2015	FDA Approves Lucentis (ranibizumab) to Treat Diabetic Retinopathy in People with Diabetic Macular Edema
Aug 18, 2013	FDA Approves Lucentis (ranibizumab) for Treatment of Diabetic Macular Edema (DME)
Mar 25, 2015	FDA Approves Eylea (aflibercept) for Diabetic Retinopathy in Patients with Diabetic Macular Edema
Jul 29, 2014	Eylea (aflibercept) Injection Receives FDA Approval for the Treatment of Diabetic Macular Edema
Nov 18, 2011	FDA Approves Eylea for Wet Age-Related Macular Degeneration



## PROTOCOL S US

- Safety and efficacy of PRP to Ranibizumab 0.5 mg injections for the treatment of PDR
- 55 US centres
- 394 eyes of 304 patients with active PDR

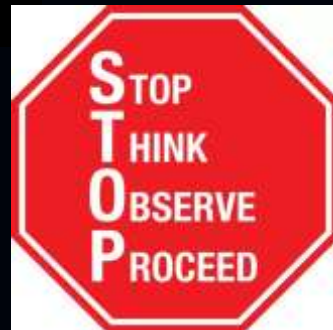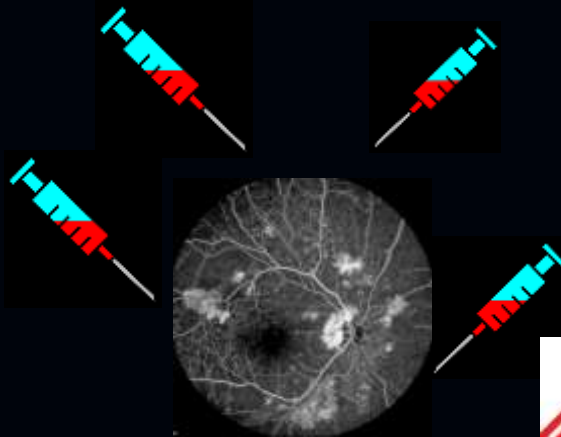


## CLARITY UK

- One year safety and efficacy of PRP vs intravitreal Aflibercept for the treatment of PDR
- 232 patients randomised
- 22 UK centres

Comparison of the primary outcome, best corrected visual acuity, between treatment groups at 12 weeks and 52 weeks

	n		Mean (SD)		Change from baseline Mean (SD)		Adjusted difference between groups (95% CI)	p value
	PRP	Aflibercept	PRP	Aflibercept	PRP	Aflibercept		
Baseline	110	110	81.9 (8.6)	80.5 (8.3)	-	-	-	-
At 12 weeks								
Intention to treat	101	109	81.3 (7.8)	82.6 (9.6)	-0.8 (0.4)	1.4 (0.5)	2.1 (0.5-3.7)*	0.0100
Per protocol	99	103	81.3 (7.9)	82.7 (9.7)	-0.9 (0.4)	1.5 (0.6)	2.1 (0.6-3.6)*	0.0074
At 52 weeks								
Intention to treat	104	105	79.1 (9.7)	82.4 (10.4)	-3.0 (0.7)	3.3 (0.6)	3.9 (2.3-5.4)*	-0.0001
Per protocol	102	98	79.3 (9.3)	82.6 (10.1)	-2.9 (0.7)	4.3 (0.6)	4.0 (2.4-5.7)*	-0.0001




# Intravitreal Anti-VEGF

- Needs longer follow up period
- More frequent visits
- Patient anxiety
- More data is needed about visual stability

Cost-effectiveness of Intravitreal Ranibizumab Compared With Panretinal Photocoagulation for Proliferative Diabetic Retinopathy: Secondary Analysis From a Diabetic Retinopathy Clinical Research Network Randomized Clinical Trial

Table 1. Mean per-Patient Costs of Ranibizumab and Panretinal Photocoagulation Groups Over 2 Years of Follow-up (in 2016 US Dollars)

Cost Category	Ranibizumab (n = 212)		Panretinal Photocoagulation (n = 212)	
	Mean (SD)	95% CI	Mean (SD)	95% CI
Diabetic retinopathy procedures	808	1,759	508	1,287
Anti-VEGF injection procedures	607	133	317	26
Anti-VEGF injection materials	714	1,242	177	211.3
2.5-mg Ranibizumab	13,413	12,854	1,282	18,618
Other intravitreal therapies*	847	765	982	9
Other intravitreal therapies†	763	184	942	9
Systemic adverse events‡	1986	2062	1298	1412
<b>Total</b>	<b>24,526</b>	<b>29,374</b>	<b>7442</b>	<b>22,379</b>



Anti-VEGF Monotherapy cost \$16,238 - \$19,150

# Pan Retinal Photocoagulation



Macular edema



Vitreous Hemorrhage

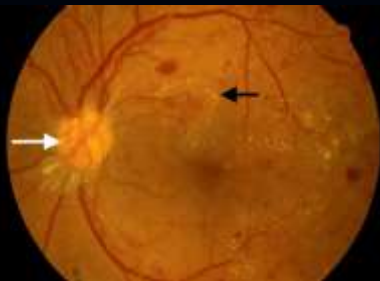

Constricted field


- Reduces severe visual loss by 96%
- 4.5% of PRP treated PDR patients require vitrectomy surgery
- Can be completed in 1-3 sessions
- Cost \$6,297 - \$7,988

Flynn HW, Jr, et al. 3rd Pars plana vitrectomy in the Early Treatment Diabetic Retinopathy Study. ETDRS report number 17. The Early Treatment Diabetic Retinopathy Study Research Group. *Ophthalmology*. 1992;99(9):1351-1357

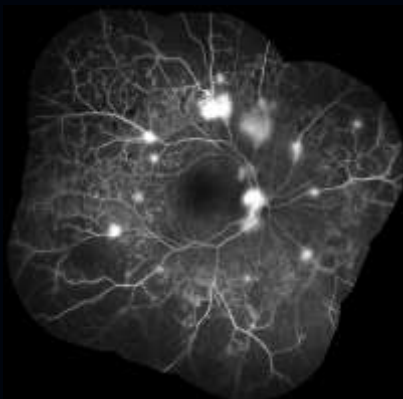## Clinical Examples



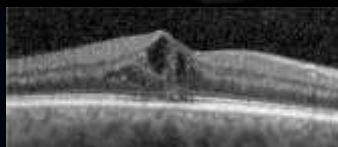
65 year old male  
30+ years DM  
From Sohag





PRP



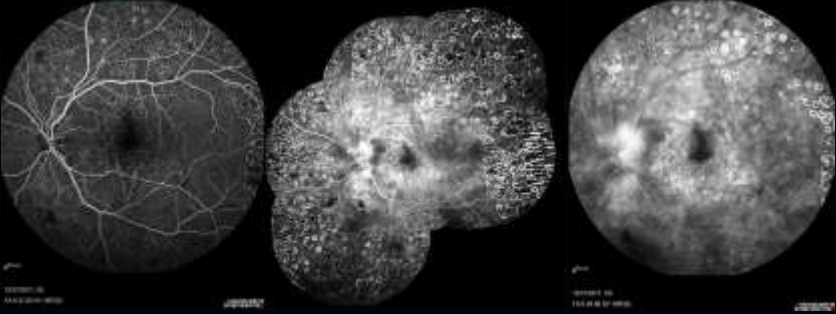
42 year old female  
10 years DM  
From Cairo



Anti- VEGF + PRP

28 year old male  
2 years IDDM  
From Alexandria




Anti- VEGF

## Messages in 2017

- Diabetes is a chronic disease
- Anti-VEGFs work **better** in PDR + DME
- Optimum Treatment
  - Tailored
  - Patient centered







**If we open a quarrel between past  
and present, we shall find that we  
have lost the future.**

Winston Churchill

Thank you for your attention